

# HEMI HAMATE ARTHROPLASTY FOR UNSTABLE PIP JOINT FRACTURE DISLOCATIONS OF THE FINGER

Dr. Ekjot Singh Arora

Dr. Sandeep Shaina

Dr. B.P. Sharma

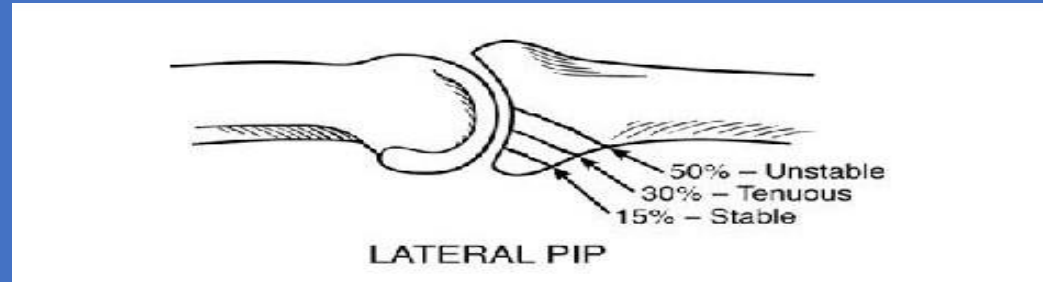
Central institute of  
Orthopaedics

VMMC & Safdarjung  
hospital, New Delhi.



# INTRODUCTION

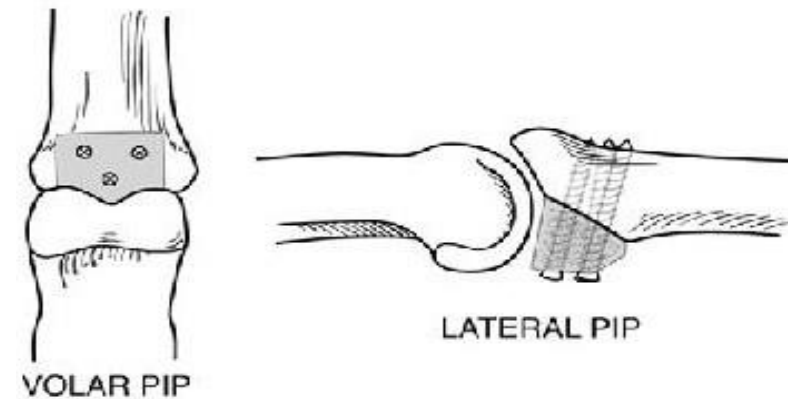
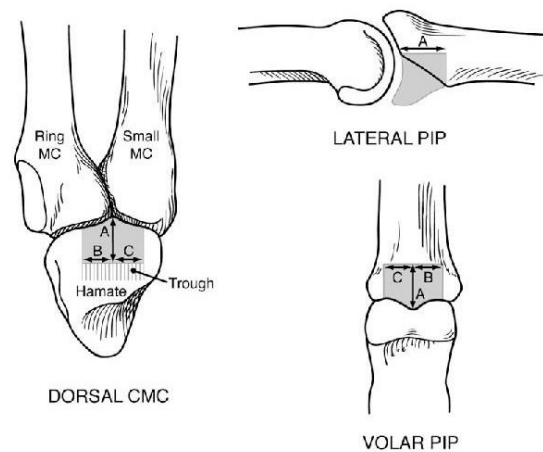
- Proximal interphalangeal joint (PIP) of the finger is a bicondylar joint , injury to which can lead to stiffness and angulation if not treated adequately and timely.
- The injury has been classified according to the amount of articular surface involvement and therefore , the management varies in each case.



## AIM

To show that Hemi Hamate Arthroplasty restores joint stability and function in UNSTABLE fractures of proximal end of middle phalynx of the finger .

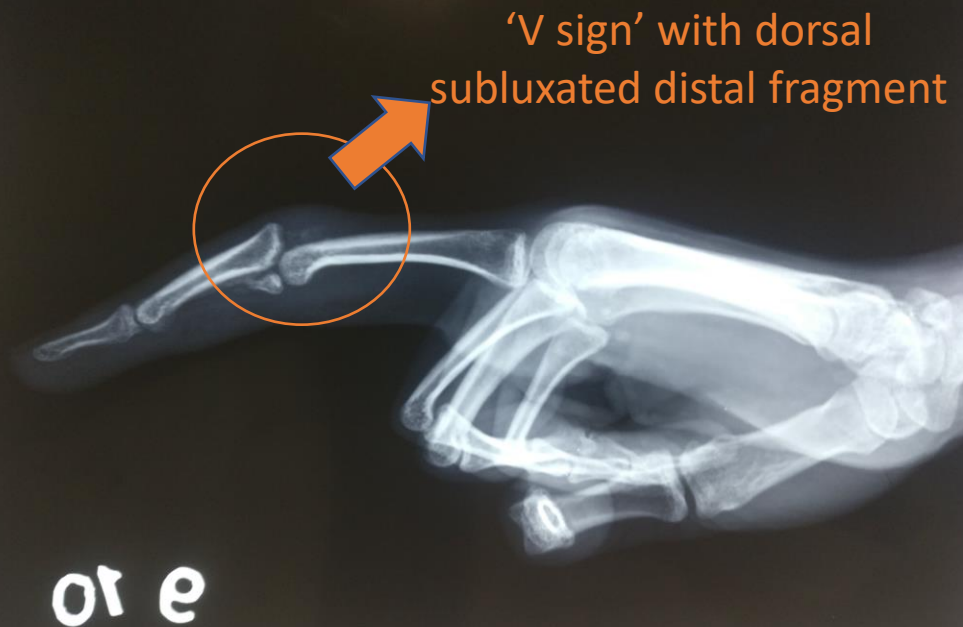# CONCEPT



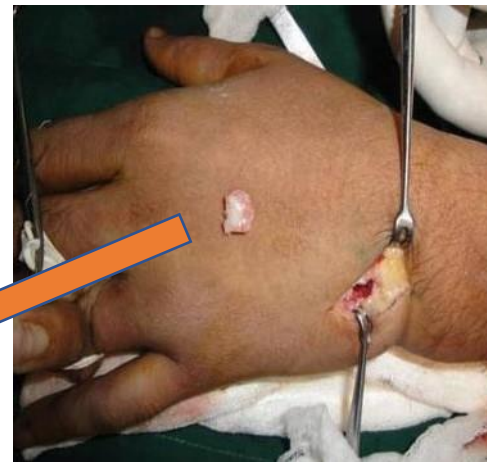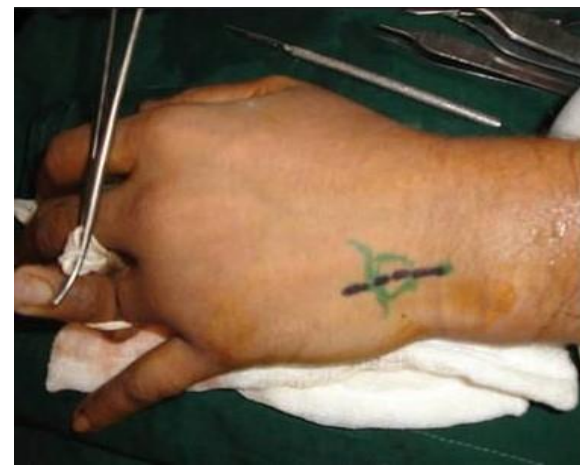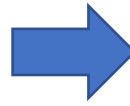
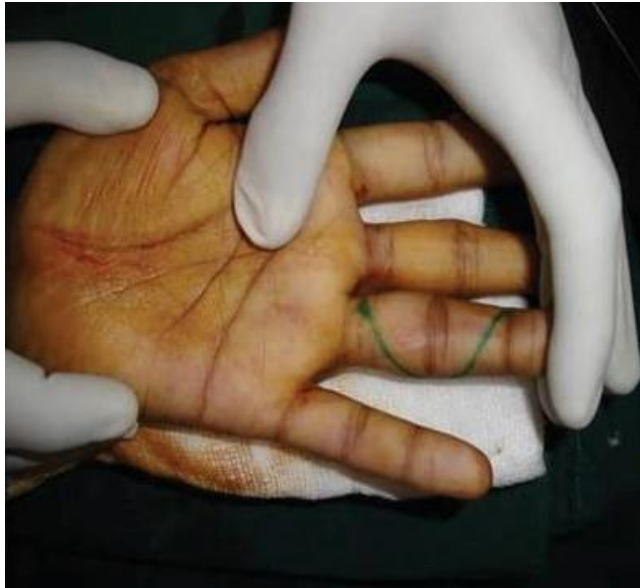## CASE HISTORY

A 17 yr old male presented to Safdarjung hospital orthopaedic opd with a history of recent trauma to the middle finger of his hand due to a cricket ball. Patient complaints of pain , swelling and deformity of the middle finger.

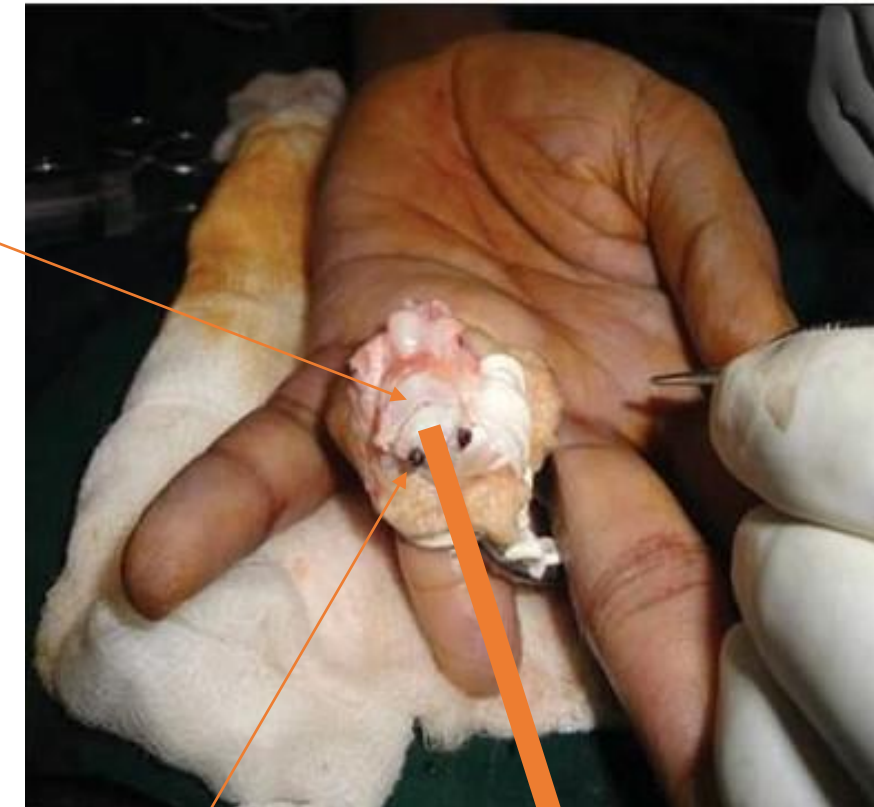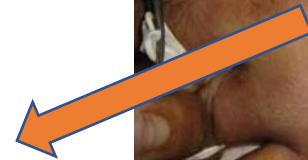## PRE-OP XRAY



# METHODS



Hamate Autograft



Middle Phalynx



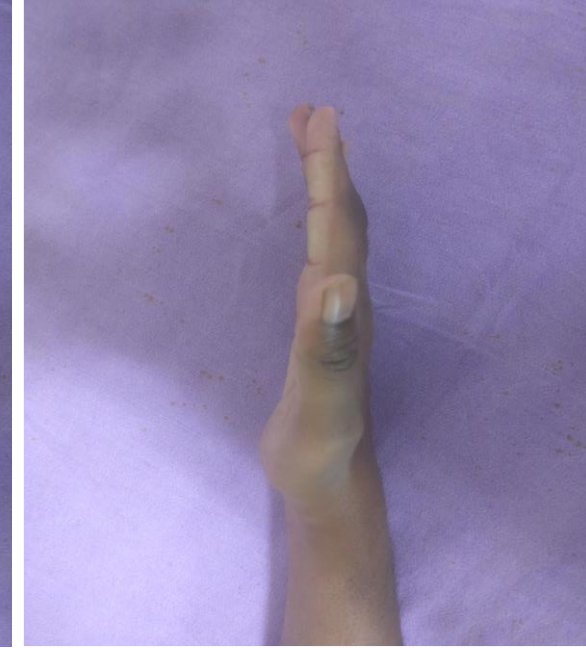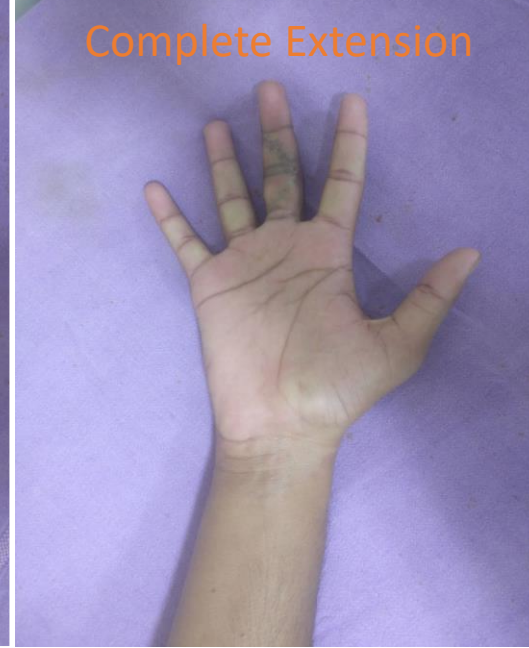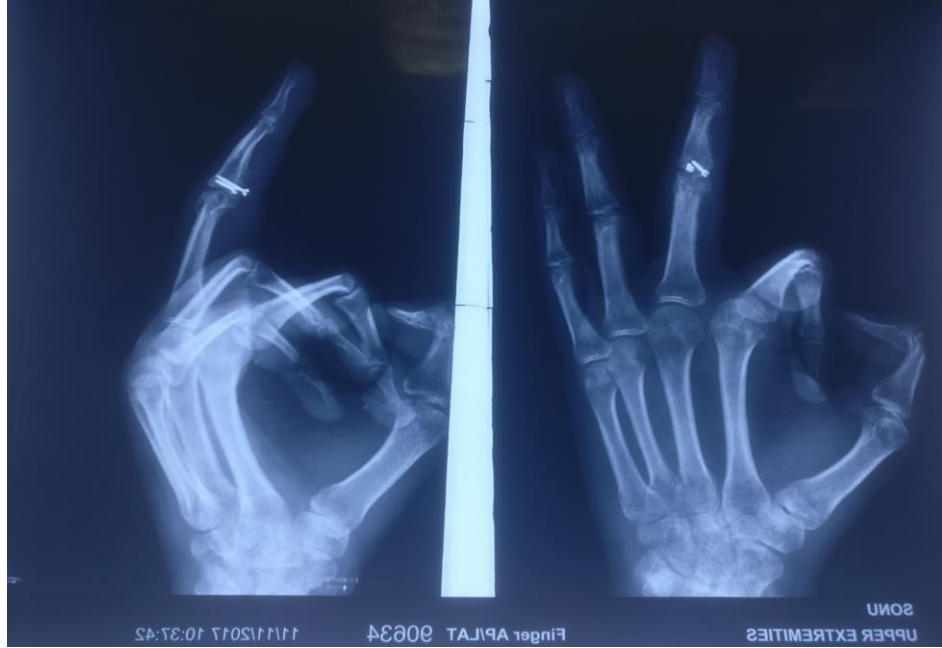1.5 mm mini fragment screw (Ao)



Hamate graft in situ



- Follow up xray of the patient showing union of the hamate graft at the fracture site with implant in situ
- Clinical images post rehabilitation showing full range of motion at the joint and the patient was pain free during all motions



## CONCLUSION

Hemi-hamate resurfacing arthroplasty procedure is the treatment of choice in unstable PIP joint fracture dislocations with articular surface involvement >50%. It is a preferred alternative to volar plate arthroplasty.

## REFERENCES

- Korambayil PM, Francis A. Hemi-hamate arthroplasty for pilon fractures of finger. Indian J Plast Surg 2011;44:458-66.
- Calfee RP, Kiefhaber TR, Sommerkamp TG, Stern PJ. Hemihamate arthroplasty provides functional reconstruction of acute and chronic proximal interphalangeal fracture-dislocations. J Hand Surg 2009;34:1232-41.