

A CASE OF COMPLETE TRANSECTION OF ULNAR NERVE

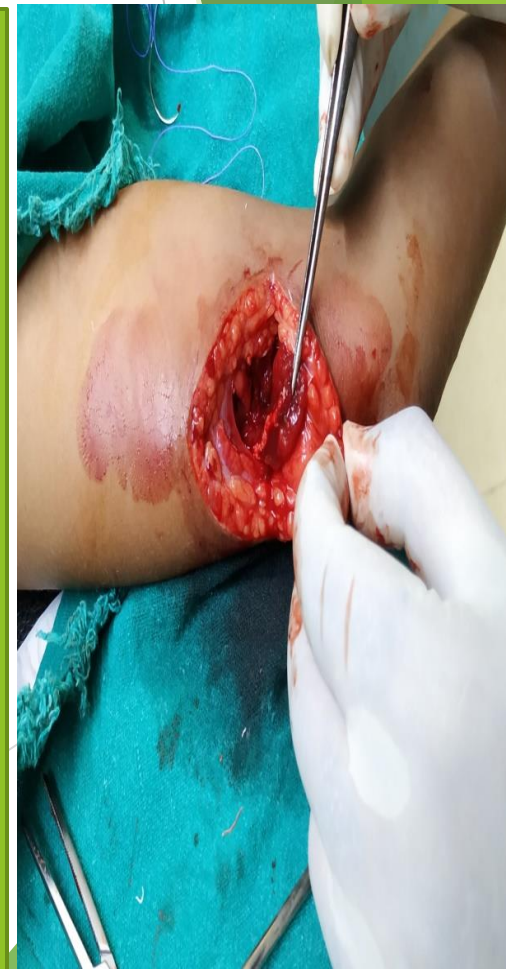DR JAIVEER SINGH
DR LOKESH KR MEENA
PG ORTHOPEDICS
PGIMSR BASAIDARAPUR N. DELHI

DR RAJAT GUPTA
SENIOR SPECIALIST ORTHOPEADICS
PGIMSR BASAIDARAPUR N. DELHI

- Patient 11 yr. old/male child presented in ortho casualty with chief complain of :
- pain and wound over postero-medial aspect of left arm
- MOI- Sharp cut mark wound by kite thread [manjha]

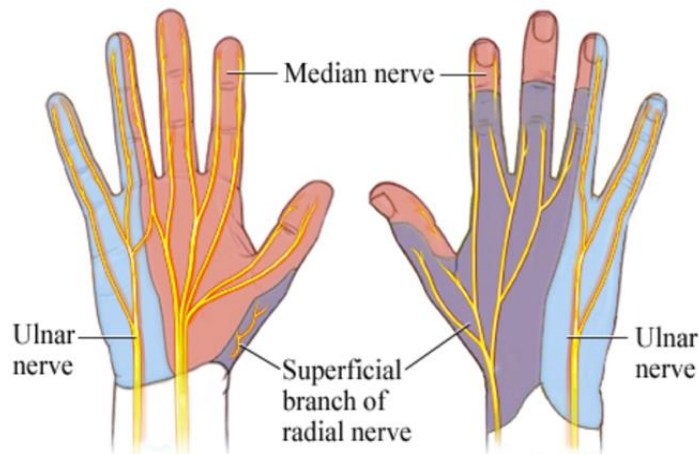
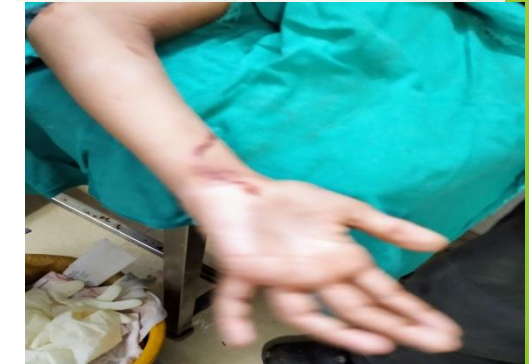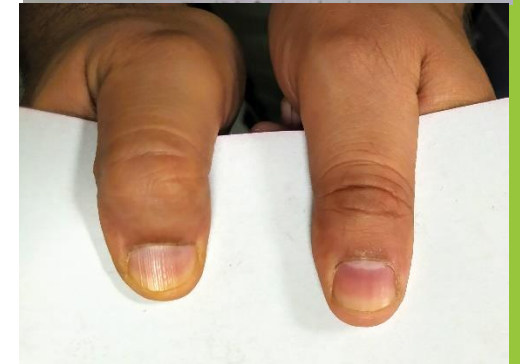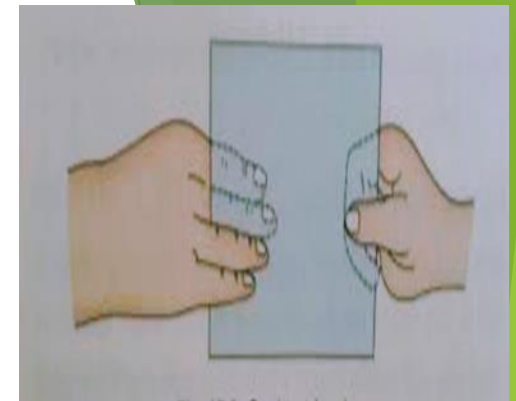
O/E- Medial head of triceps muscle was cut and ulnar nerve complete transection was seen

- Median and radial nerve examination were normal



At elbow joint-
flexion, extension, supination and
pronation -present

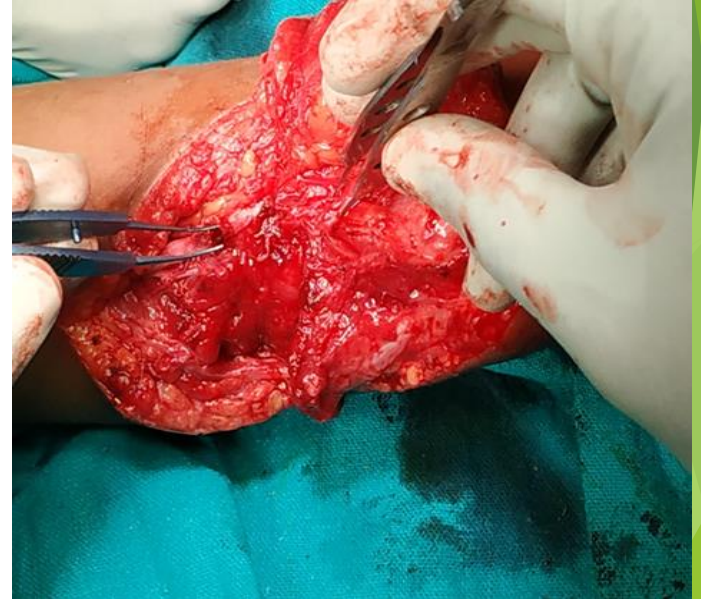- ▶ Card test – Present
- ▶ Froment sign –Present
- ▶ Ulnar Claw Hand-Present
- ▶ Sensory loss was present over ulnar aspect of left hand



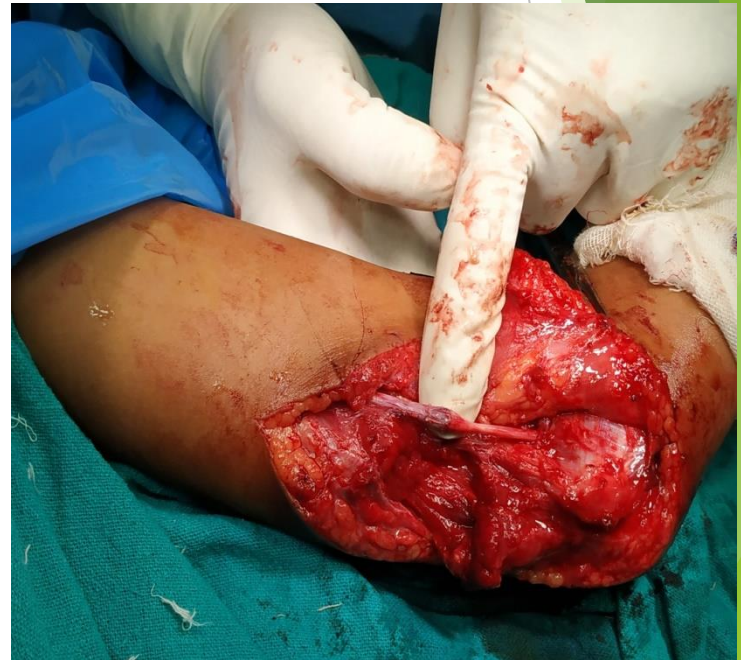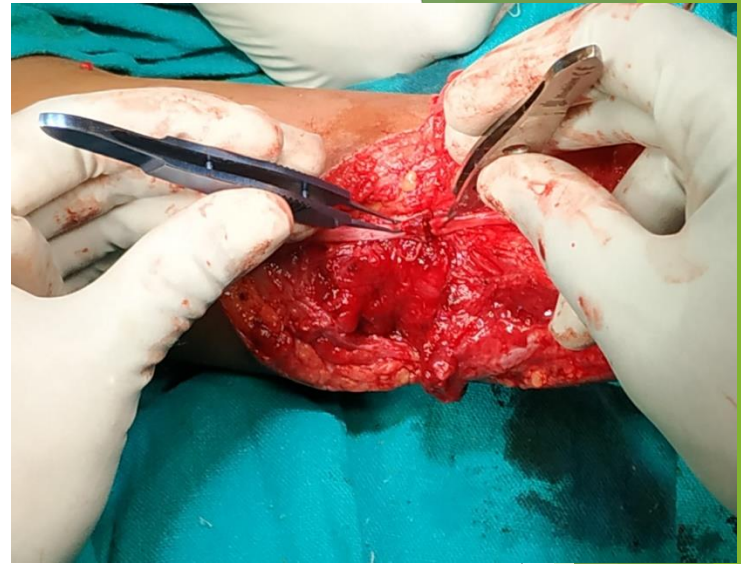
MANAGEMENT

During procedure ulnar nerve along triceps muscle's medial head was repaired

- ▶ Wound opened ulnar nerve identified
- ▶ Both end of ulnar nerve are explored along course
- ▶ Proximal fragment of nerve is explored about 5cm. And distal fragment of nerve explored till the 1st branching starts (flexor carpi ulnaris).



- ▶ Both end of dissected nerve ends are cut for 2-2 cm and margins are freshened.
- ▶ HD vascular clamp is applied to approximate and stabilized for ends of ulnar nerve
- ▶ Primary closure of both end's epineurium of ulnar nerve was done by ethylon 9-0 suture.
- ▶ Wound is sutured in layers and A/E extension slab given.



Discussion

- ▶ In our part of country kite thread(manjha) injury are very common which cause sharp cut and these mostly end up in transaction of nerve.
- ▶ So these injury should not ignored good result can be attained if these identified early and repair early.