

# MALLEOLAR/ANKLE NONUNIONS

DR ANKIT KHURANA  
MBBS, MS, DNB, FRCS (TR & ORTH)  
EX SR AIIMS NEW DELHI  
ASSISTANT PROFESSOR ORTHOPEDICS  
DR BSA MEDICAL COLLEGE AND HOSPITAL, GOVT OF NCT DELHI, ROHINI DELHI-110085



# FOOT AND ANKLE NON-UNIONS

- RARE


 Restricted access | Research article | First published online February 4, 2013

## Operative Treatment of Nonunion Following Distal Fibula and Medial Malleolar Ankle Fractures


[Sonya Khurana, MD](#), [Raj Karia, MPH](#), and [Kenneth A. Egol, MD](#) [View all authors and affiliations](#)

[Volume 34, Issue 3](#) | <https://doi.org/10.1177/1071100712473740>

 Contents

 Get access

 Cite article

 Share options

 Information, rights and permissions

 Metrics and

- *MALLEOLAR NONUNIONS ARE A RARE ENTITY IN ORTHOPEDIC SURGERY THAT CAN LEAD TO DEBILITATING PAIN AND LIMITED FUNCTION*



# CAUSES

- *DIABETES*
- *VASCULAR DISEASE*
- *MALNUTRITION*
- *SMOKING*



- USING A MULTIPLE POINT FIXATION, MINIMALLY INVASIVE POLAR NON-UNION ARE RELIABLY TREATED WITH OPERATIVE FIXATION AND PATIENT OUTCOMES WITH MINIMAL COMPLICATIONS



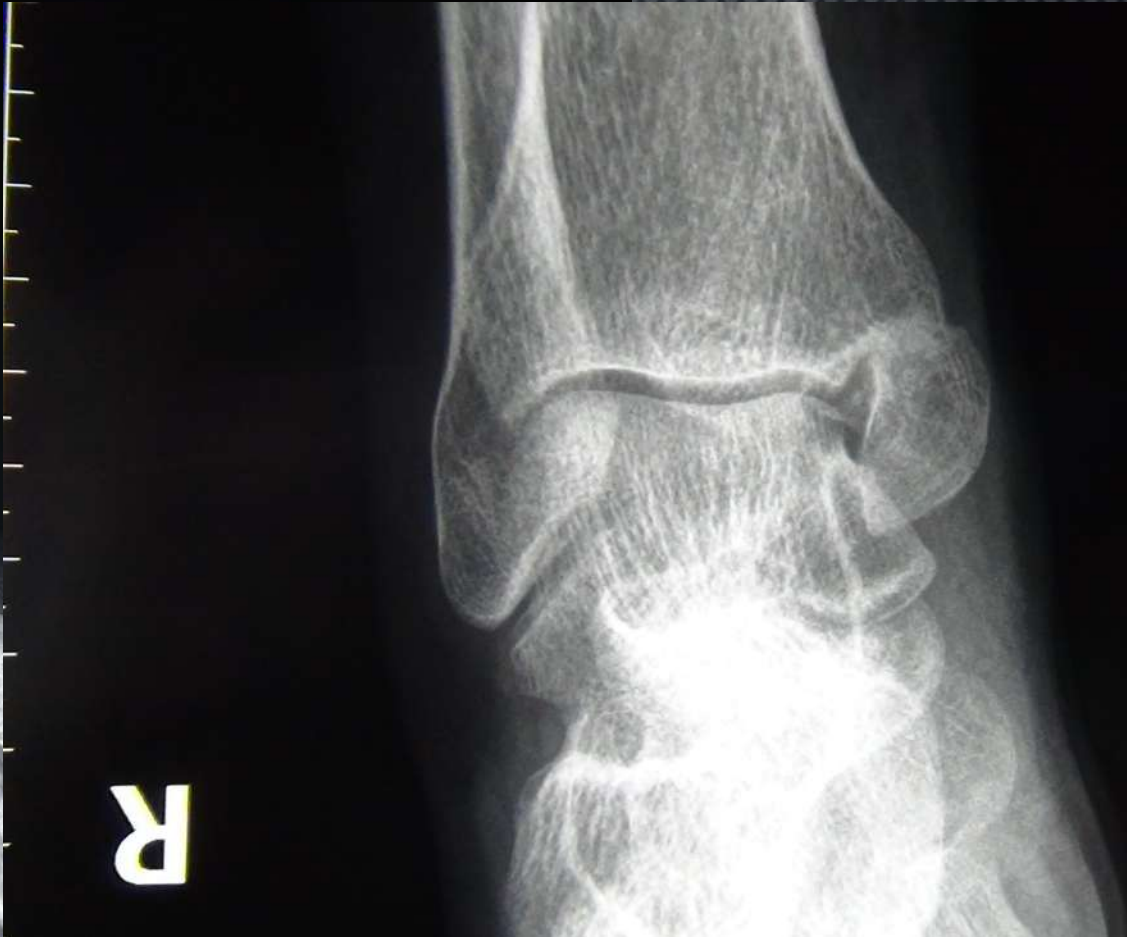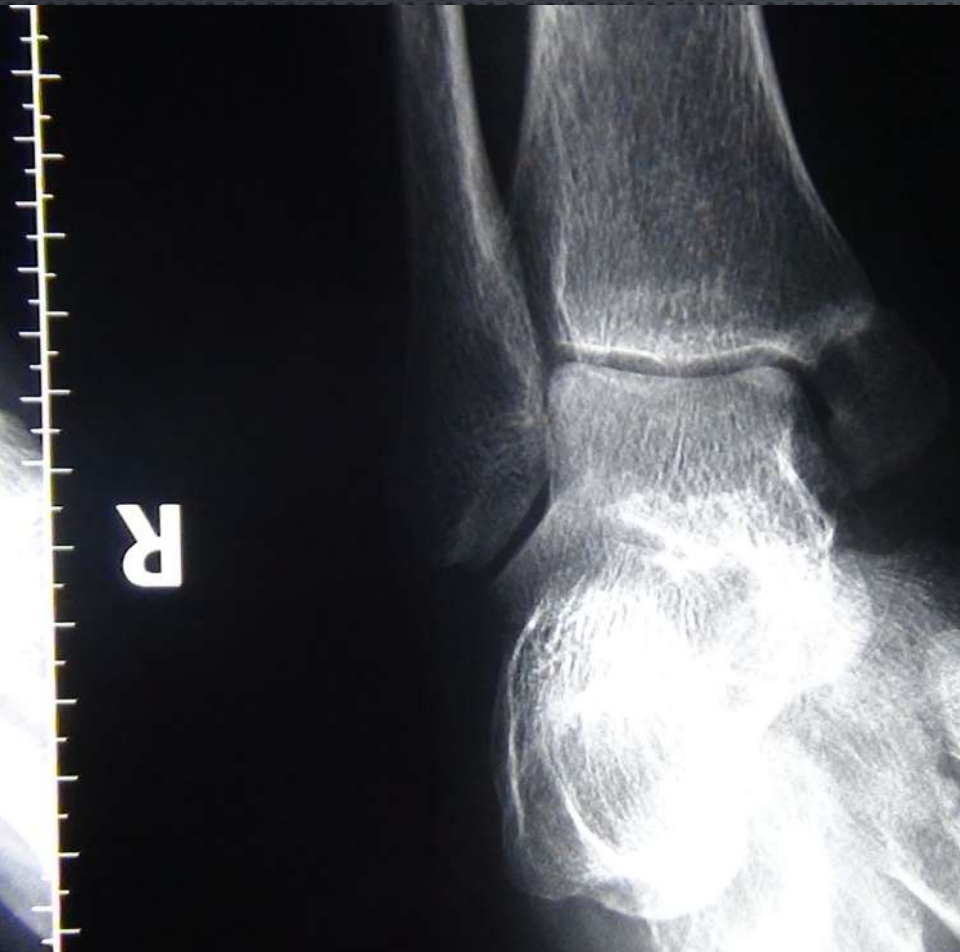# PRE-REQUISITES

- *COMPLETE HISTORY, PHYSICAL EXAMINATION, RADIOGRAPHS, AND ROUTINE LABORATORY EXAMINATIONS.*
- *HISTORY OF DIABETES, VASCULAR DISEASE, SMOKING, OR ALCOHOL USE.*
- *PLAIN RADIOGRAPHS*
- *COMPUTED TOMOGRAPHY (CT) SCANS*



MMNU

6 Months post trauma



KN P45.17 Cor  
Im: 21

04116026

Nov 19 2014

MF:2.9

R

L R  
3 4  
9 7

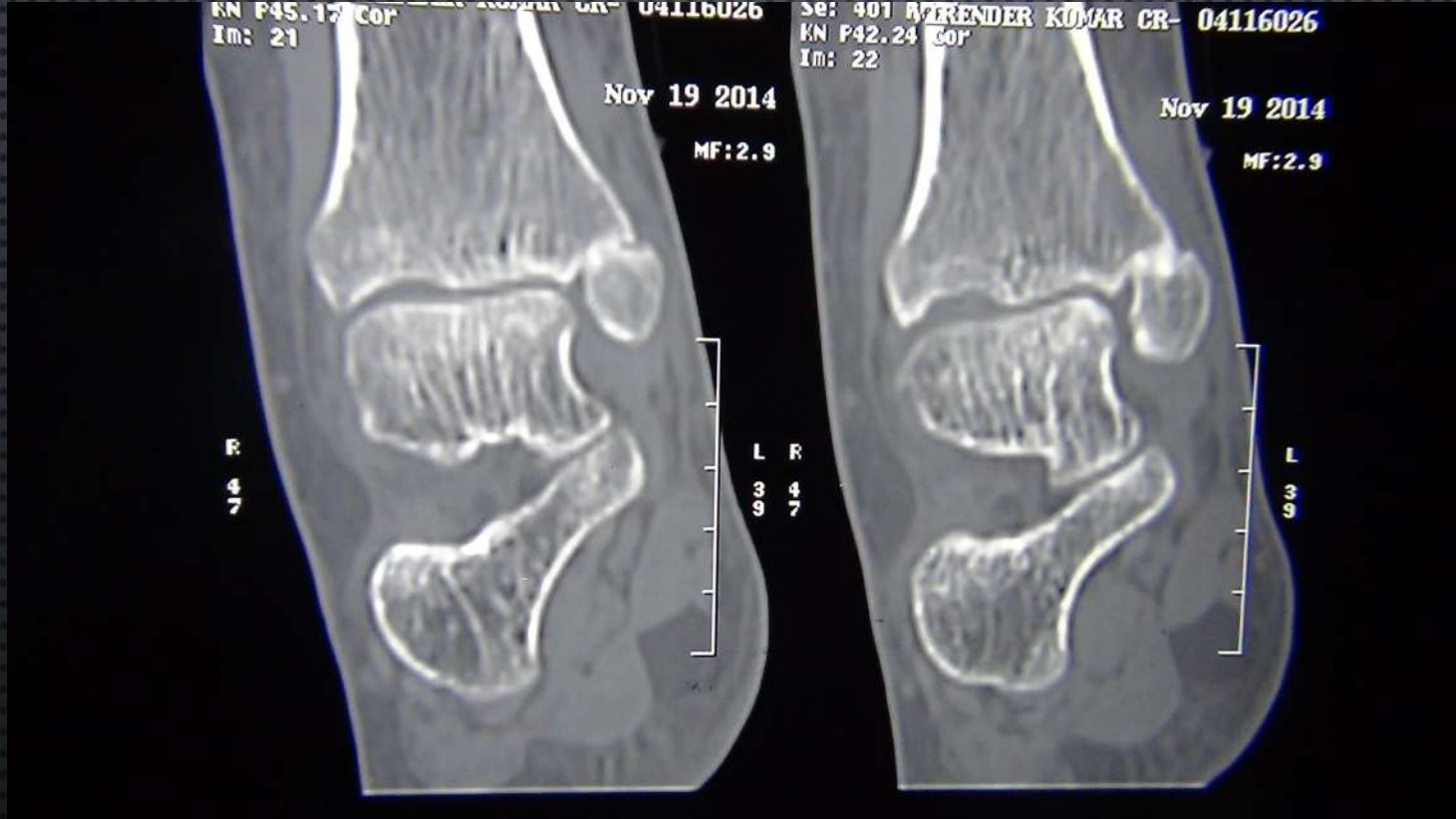Se: 401 R  
KN P42.24 Cor  
Im: 22

RENDER KUMAR CR- 04116026

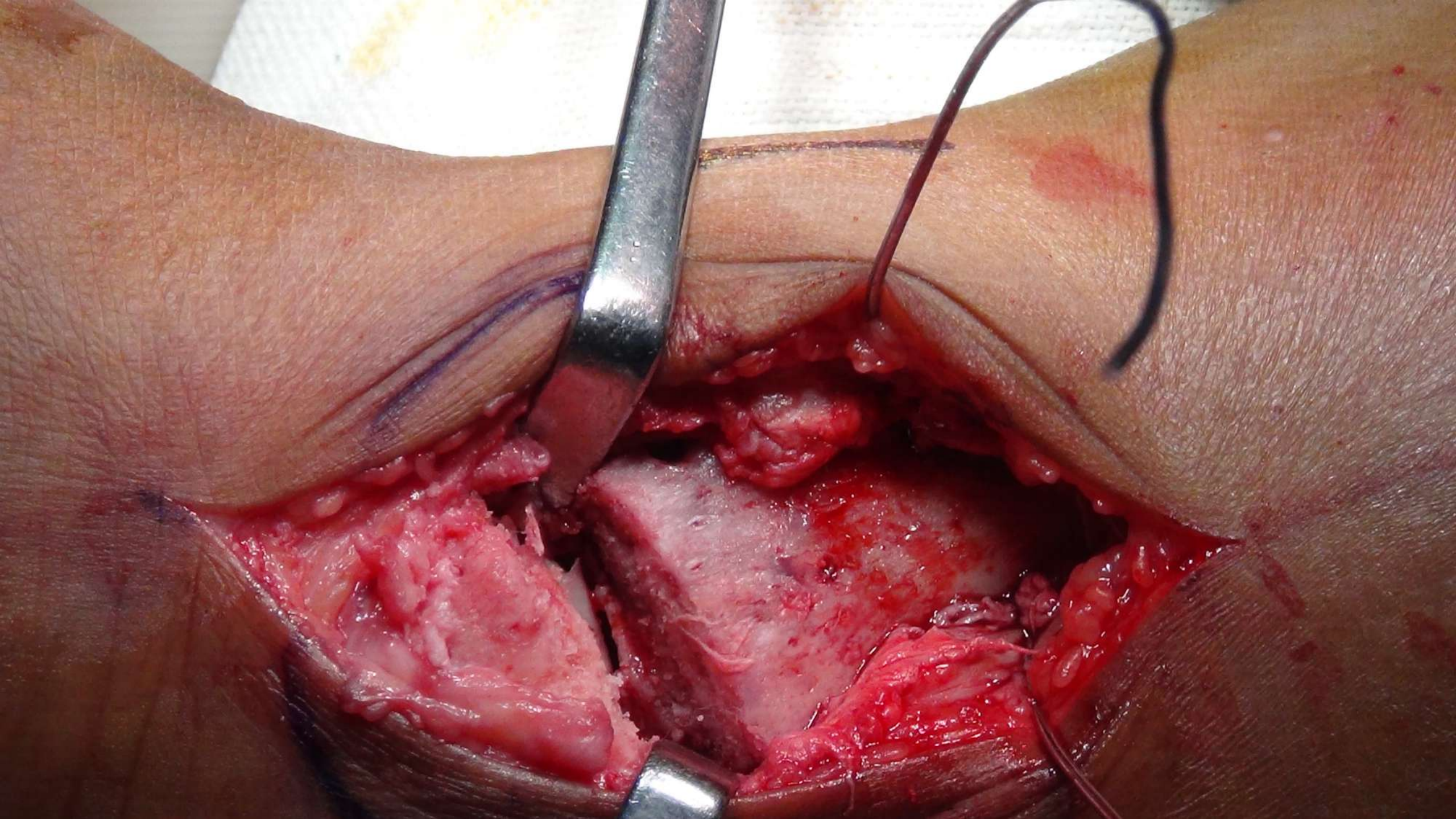
Nov 19 2014

MF:2.9

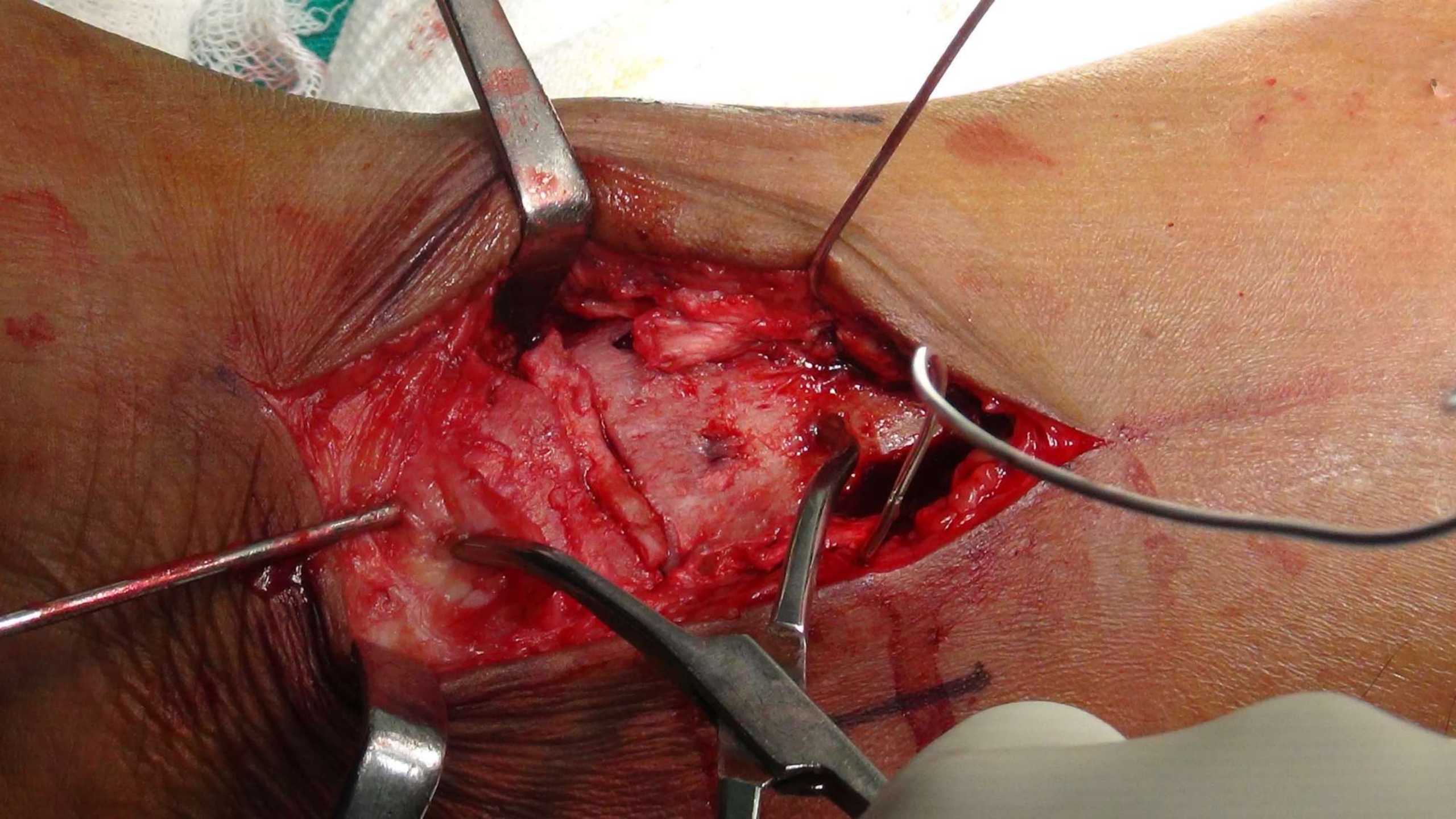
L  
3  
9



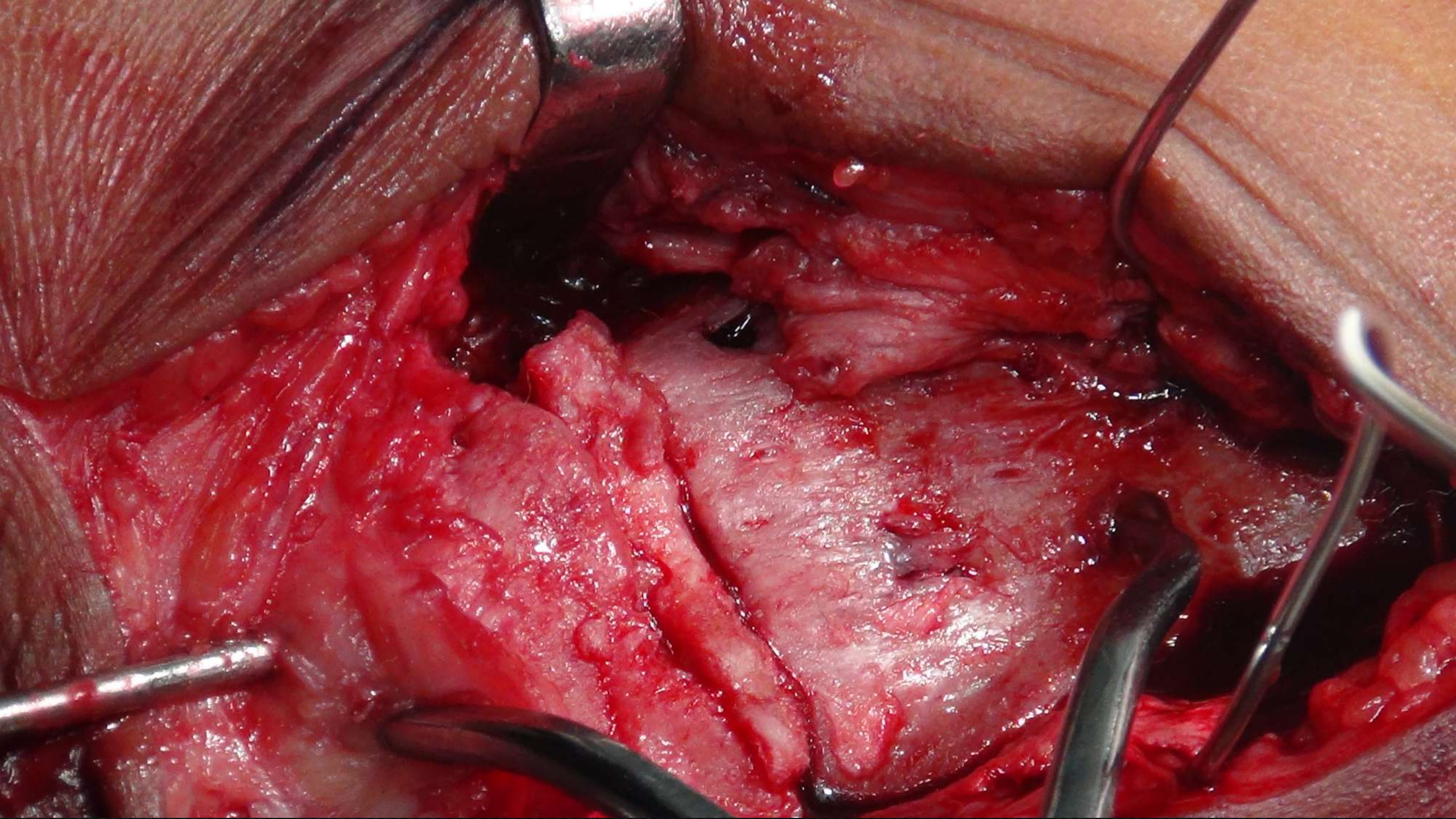




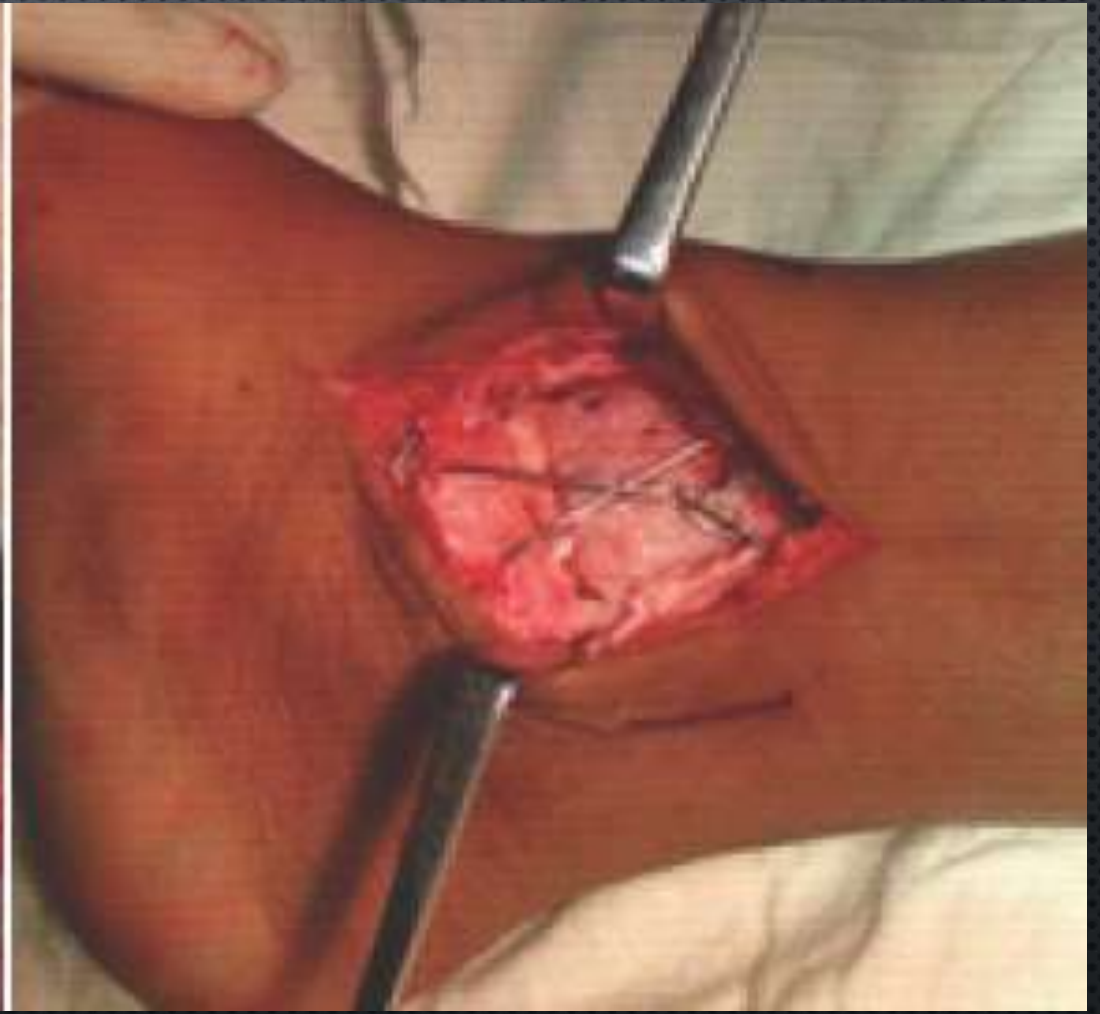
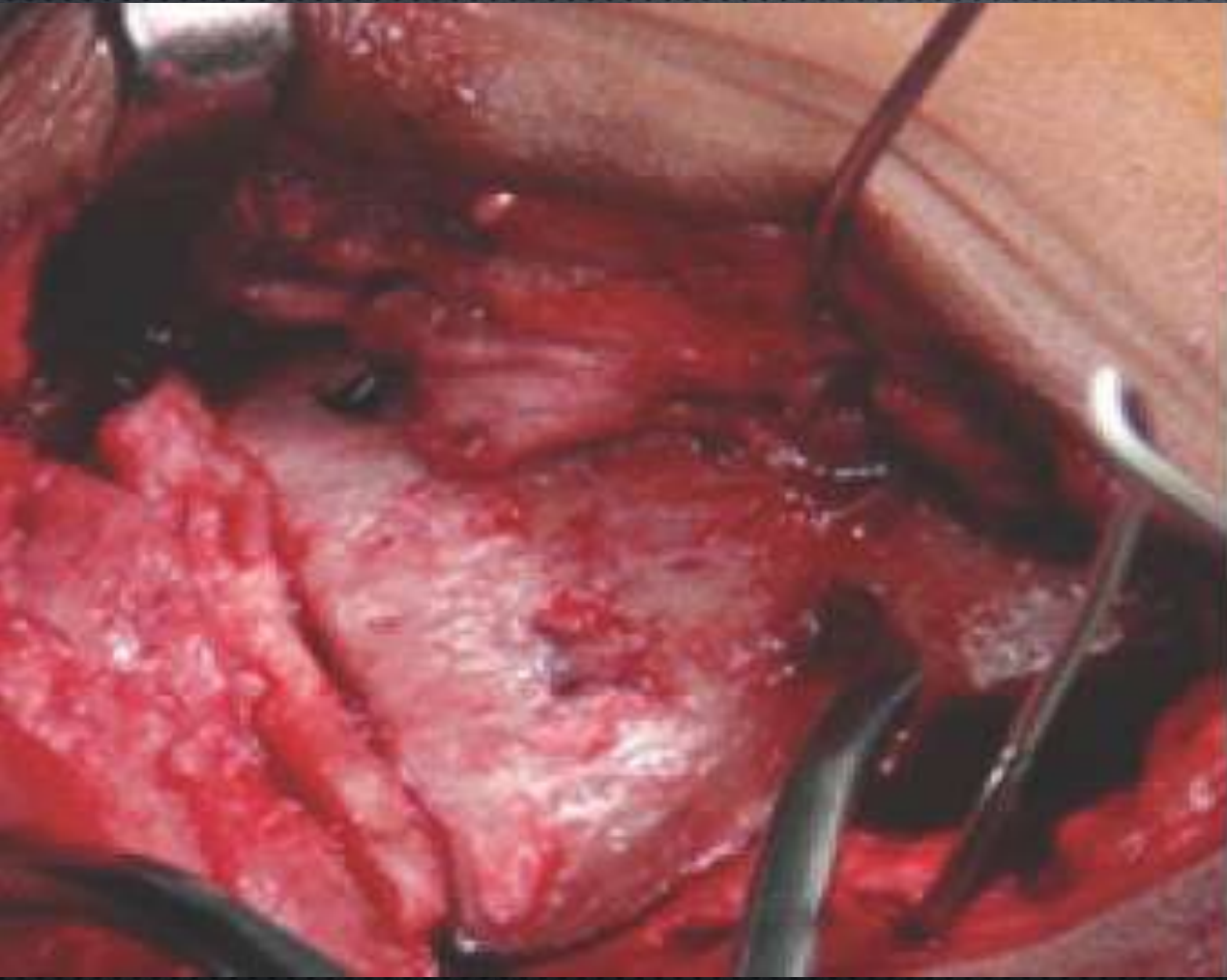




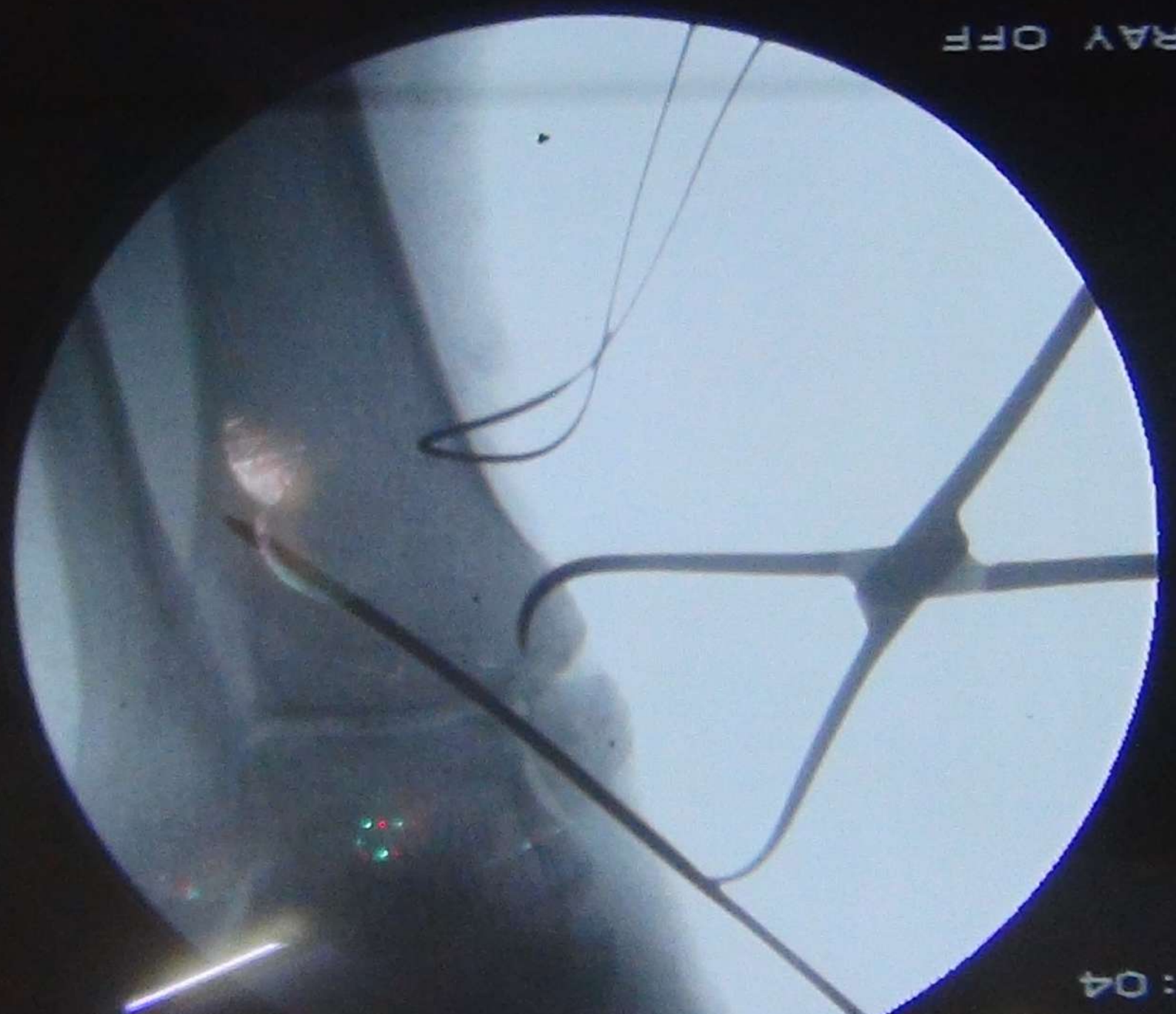










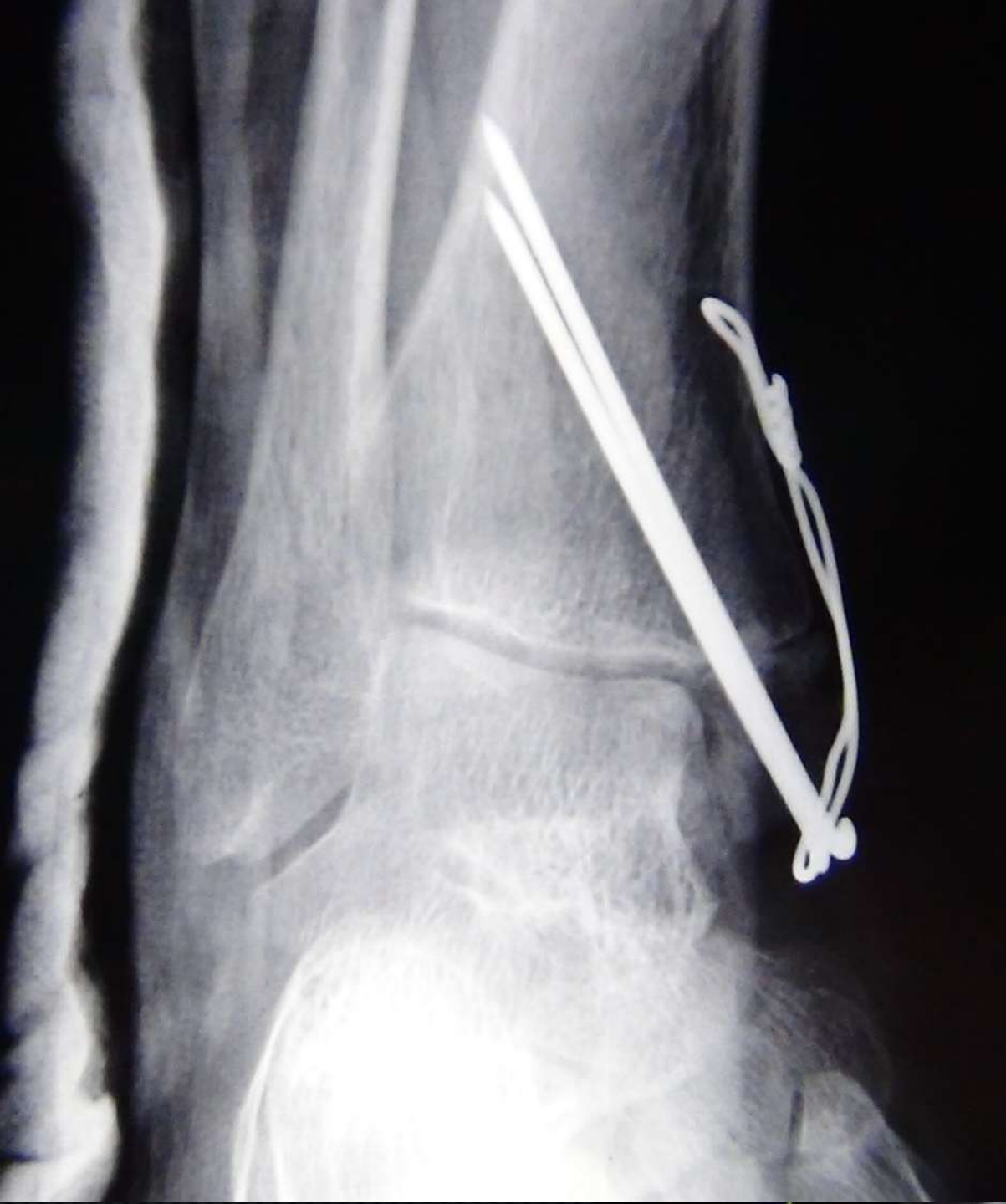
X-RAY OFF

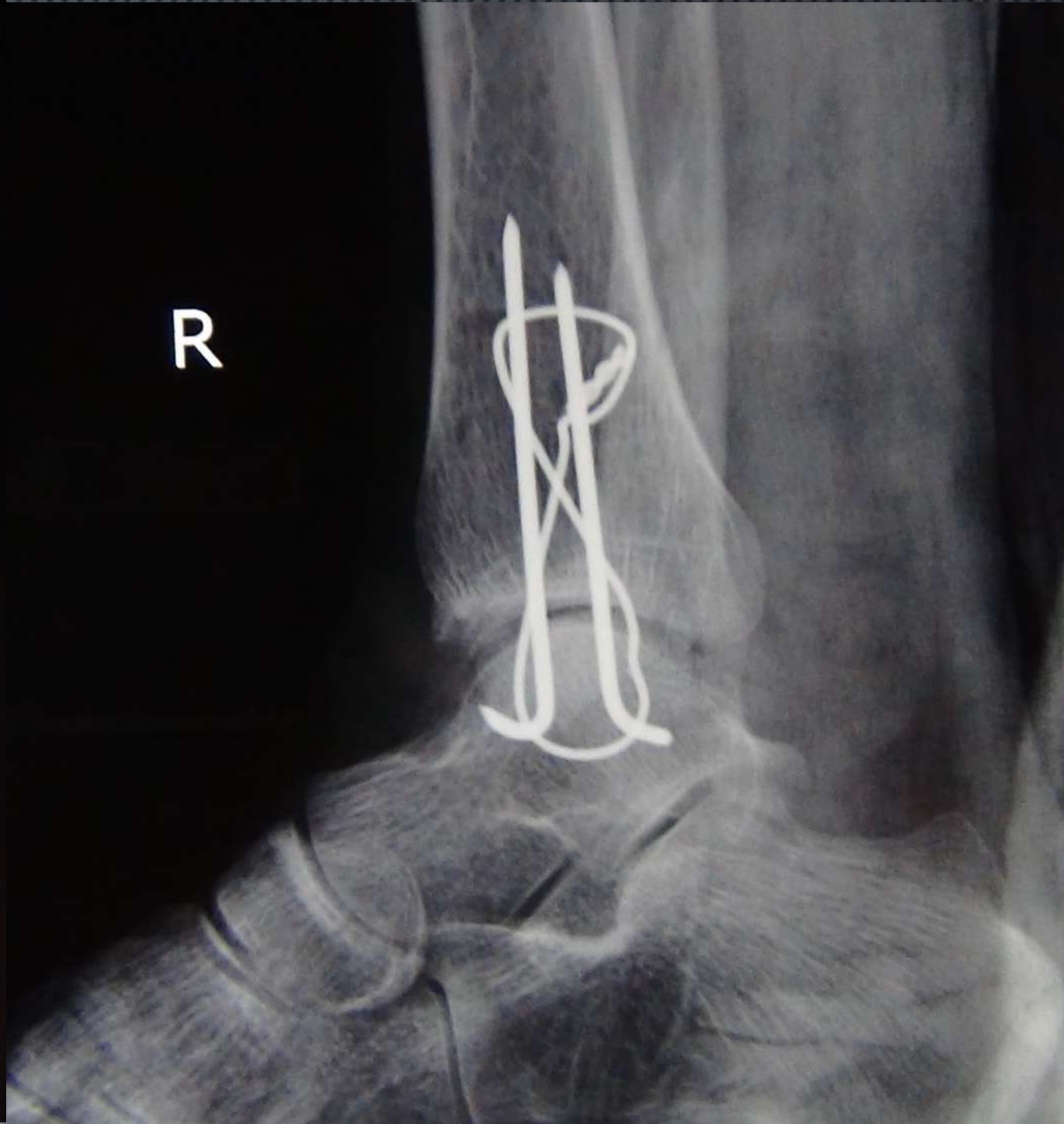
POINT: 180  
AVG: 04



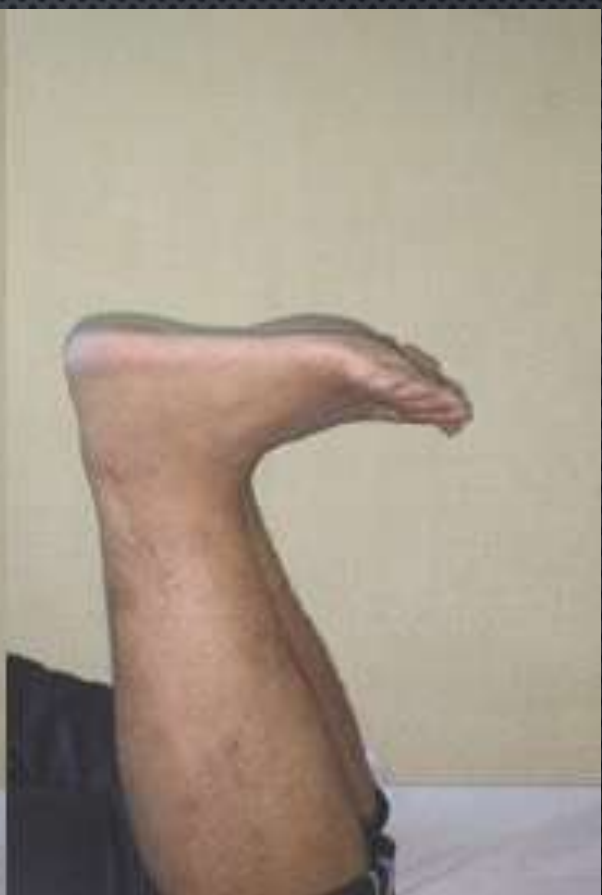
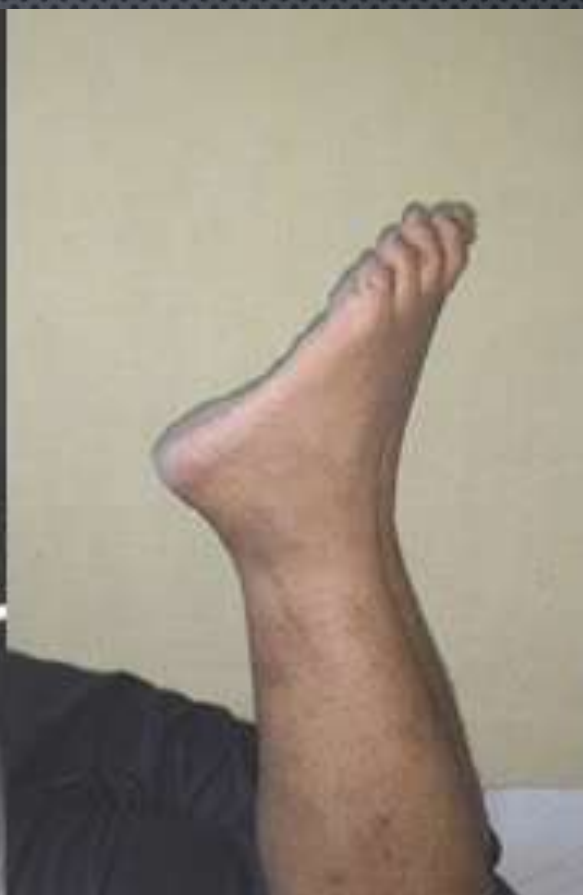
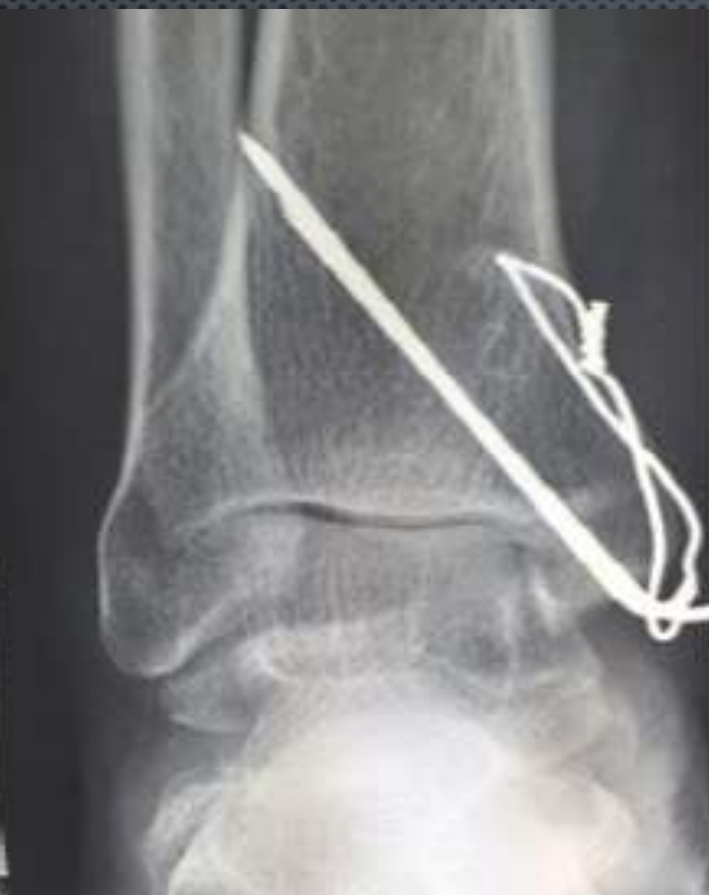
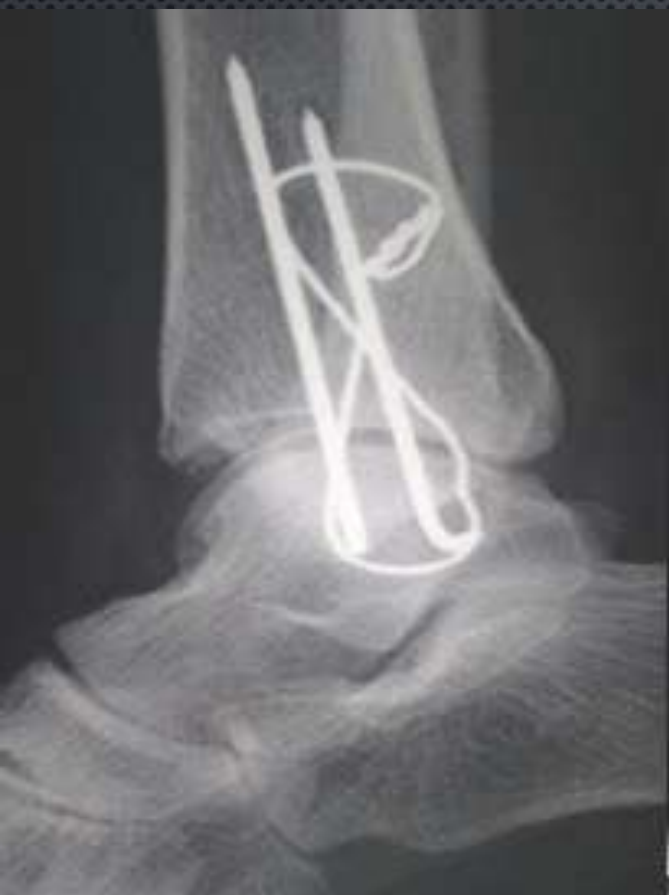
R









Found 1 result for *Tension Band Wiring Is As Effective As A Compression Screw I..*[Save](#)[Email](#)[Case Reports](#)[> J Orthop Case Rep.](#) 2017 Jul-Aug;7(4):72-75.

doi: 10.13107/jocr.2250-0685.860.

## Tension Band Wiring Is As Effective As A Compression Screw In A Neglected, Medial Maleolus Non-Union: A Case-Based Discussion & Literature Review

[Rakesh John](#)<sup>1</sup>, [Mandeep Singh Dhillon](#)<sup>1</sup>, [Ankit Khurana](#)<sup>2</sup>, [Sameer Aggarwal](#)<sup>1</sup>, [Prasoon Kumar](#)<sup>1</sup>

Affiliations – collapse

### Affiliations

- <sup>1</sup> Department of Orthopedics, Post Graduate Institute of Medical Education & Research (PGIMER), Sector 12, Chandigarh. India 160012.
- <sup>2</sup> Department of Orthopaedics, All India Institute of Medical Sciences (AIIMS), Ansari Nagar, New Delhi, India.


PMID: 29181360 PMCID: [PMC5702712](#) DOI: [10.13107/jocr.2250-0685.860](#)[Free PMC article](#)

### Abstract

**Introduction:** Isolated, neglected medial malleolus nonunion cases are a rare entity in orthopedic literature. All studies (except one) have described the use of compression screws (with or without

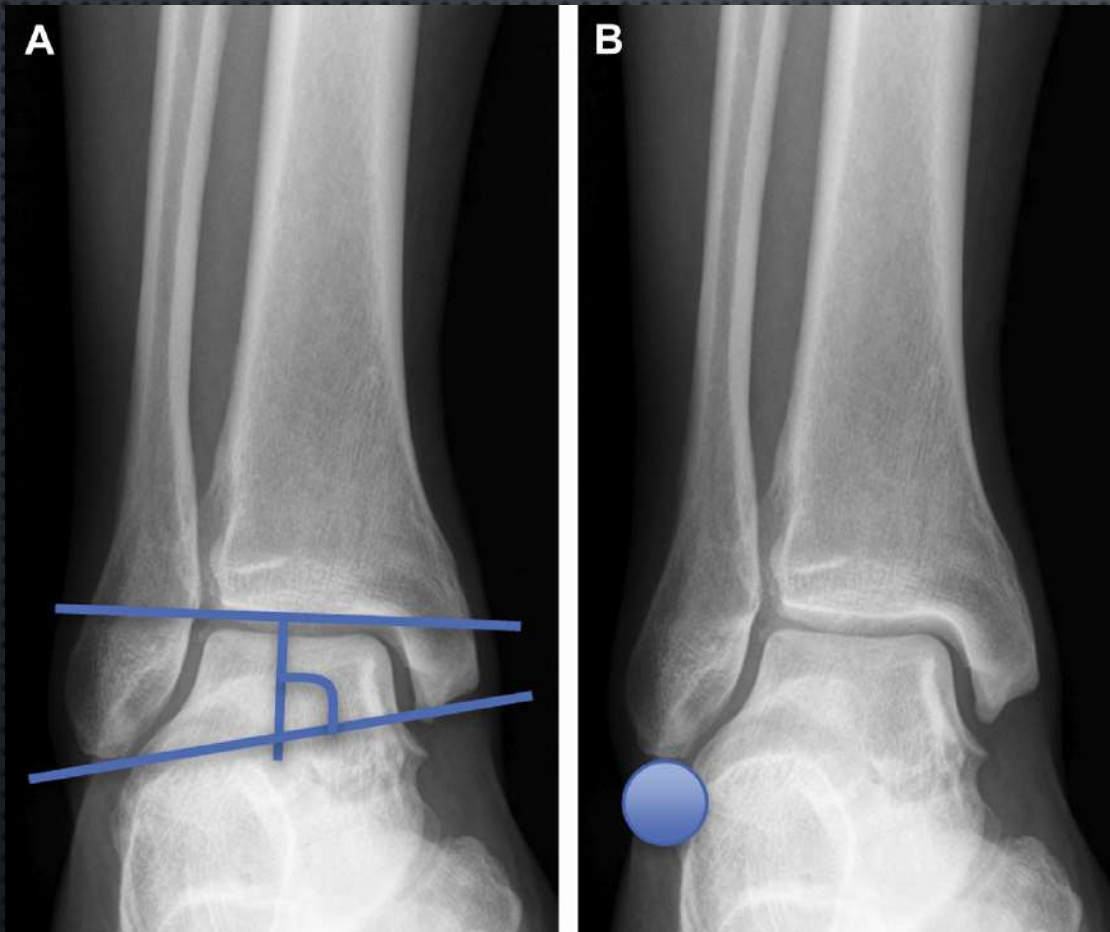


## ARTICLE CONCLUSIONS (2017)

- TBW MAY BE **BETTER**  **SCREW FIXATION** IN THE MANAGEMENT OF MEDIAL MALLEOLUS NONUNION AS IT IS TECHNICALLY STRAIGHTFORWARD AND COST-EFFECTIVE
- TBW CAN PROVIDE **EQUAL OR MORE COMPRESSION THAN A SCREW**; IT DOES **NOT DAMAGE THE SANDWICHED INLAY BONE GRAFT**, AND THE AMOUNT OF COMPRESSION IS SURGEON-CONTROLLED
- IT IS ALSO MORE SUITABLE FOR FRACTURES WITH **SMALL DISTAL FRAGMENTS AND/OR OSTEOPOROSIS**



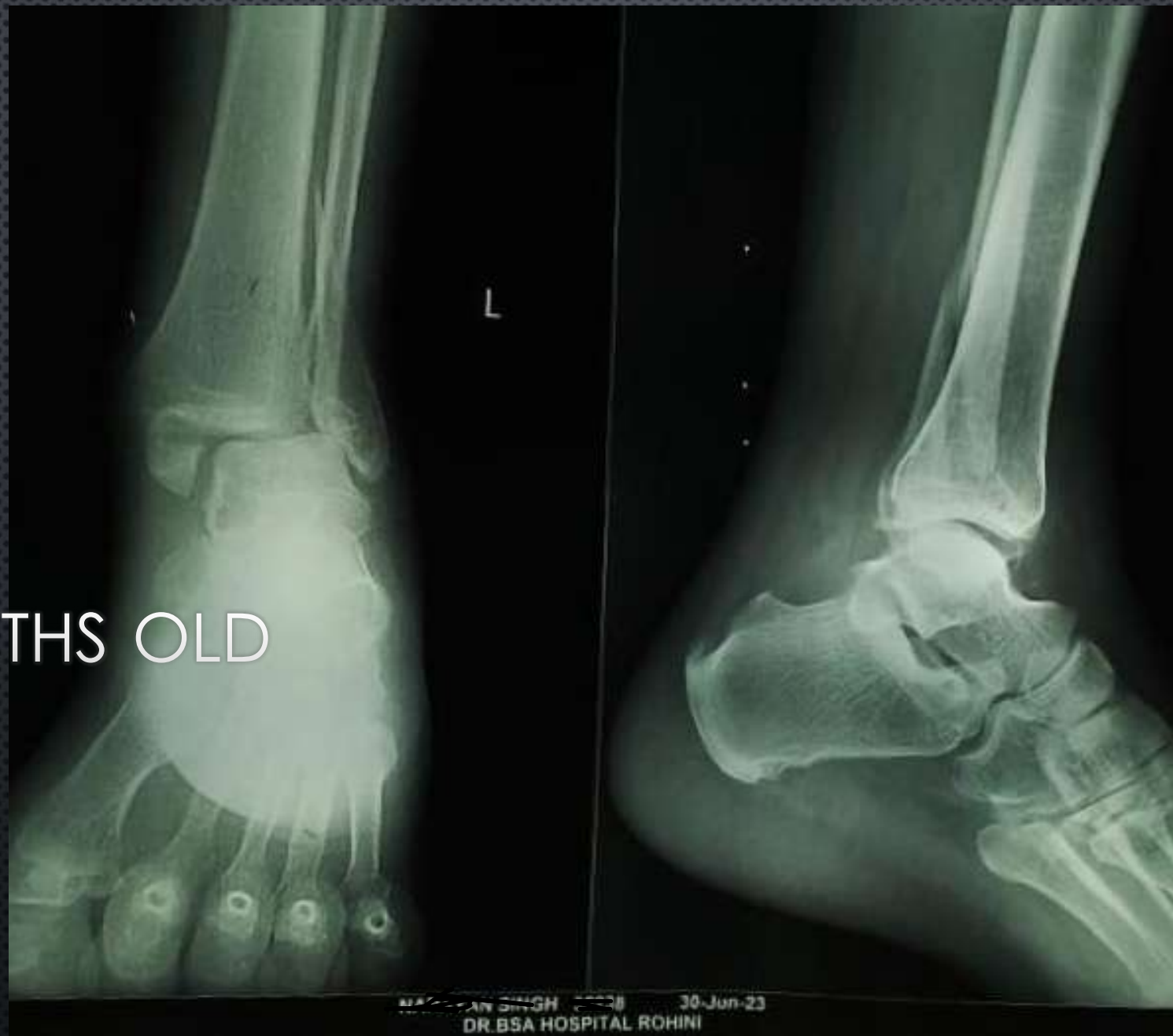# LATERAL MALLEOLUS NON UNION



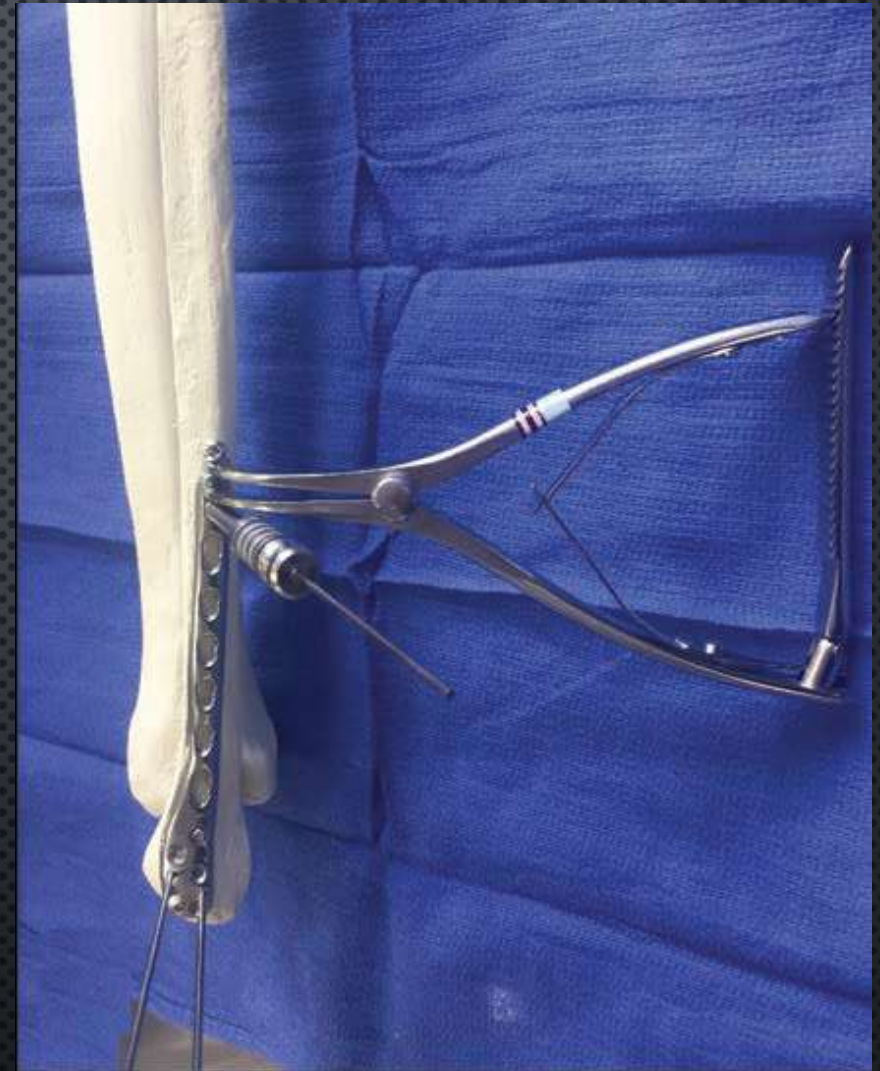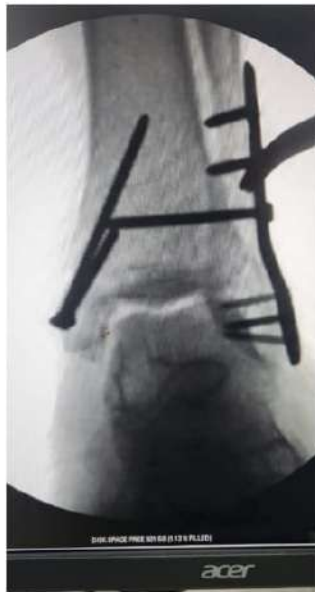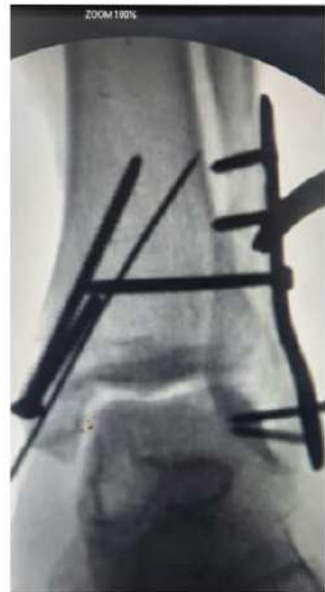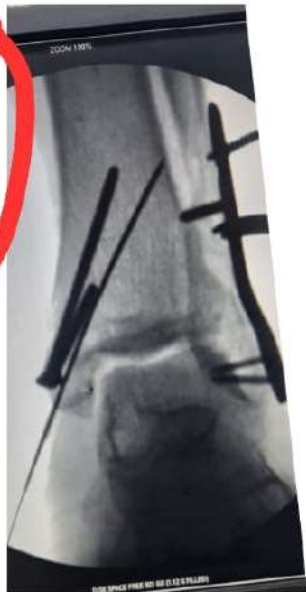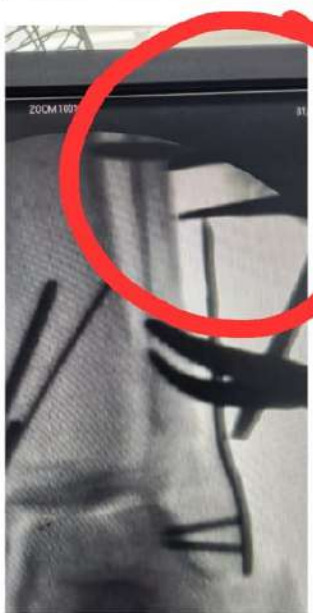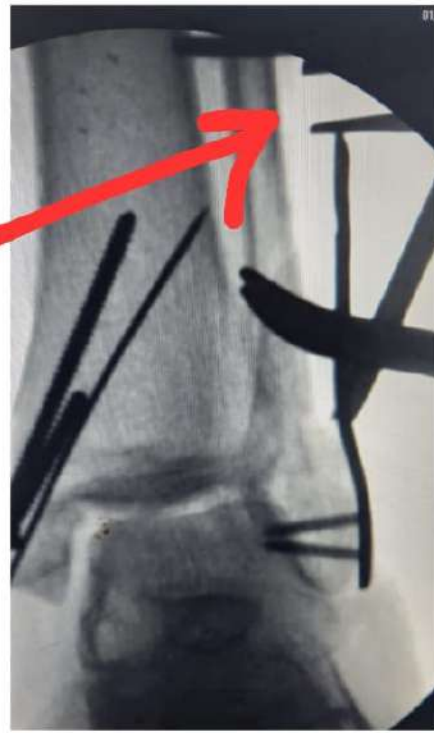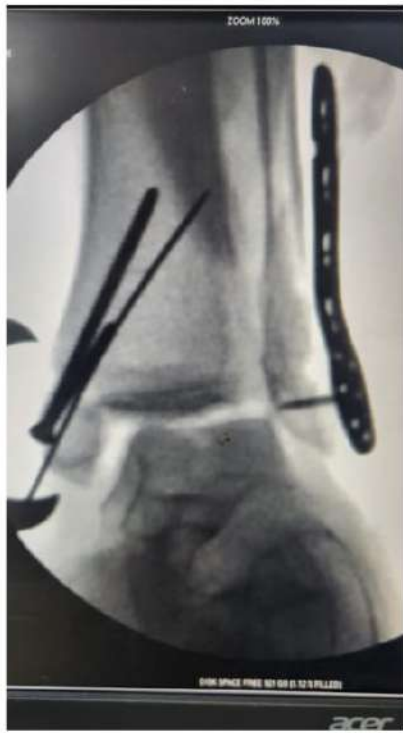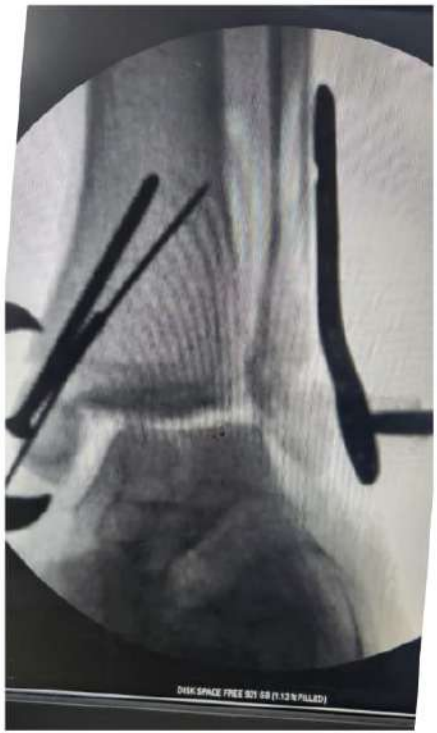- CAPOGNA BM, EGOL KA. TREATMENT OF NONUNIONS AFTER MALLEOLAR FRACTURES. FOOT ANKLE CLIN. 2016 MAR;21(1):49-62. DOI: 10.1016/J.FCL.2015.09.004. PMID: 26915778.



• 4 MONTHS OLD





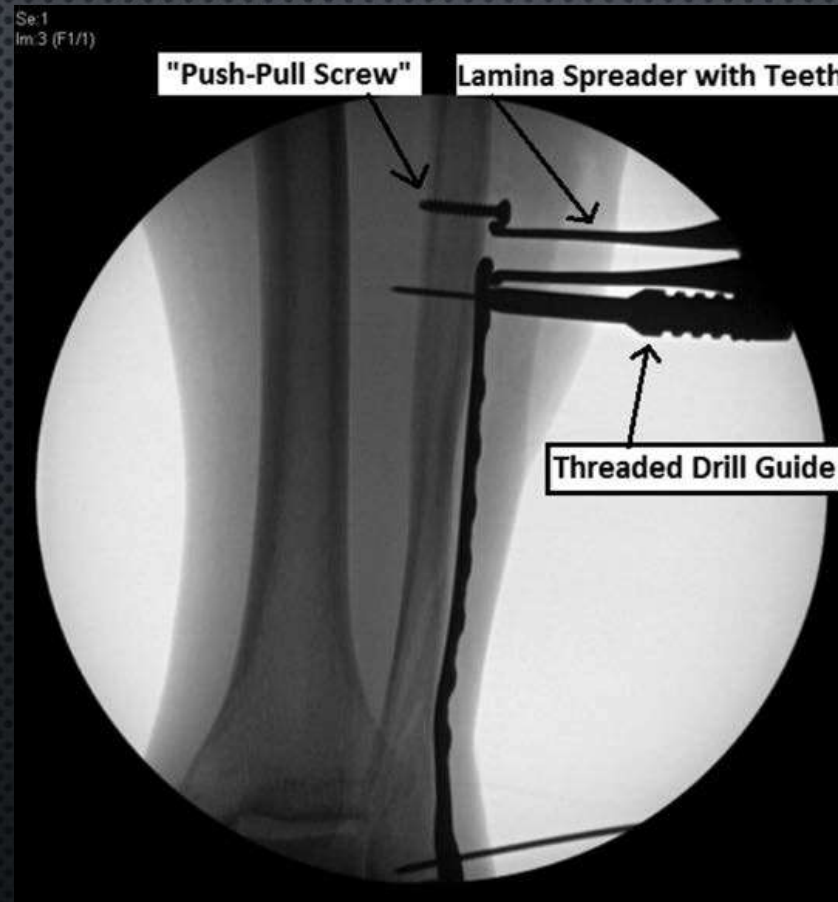


PUSH PULL TECHNIQUE



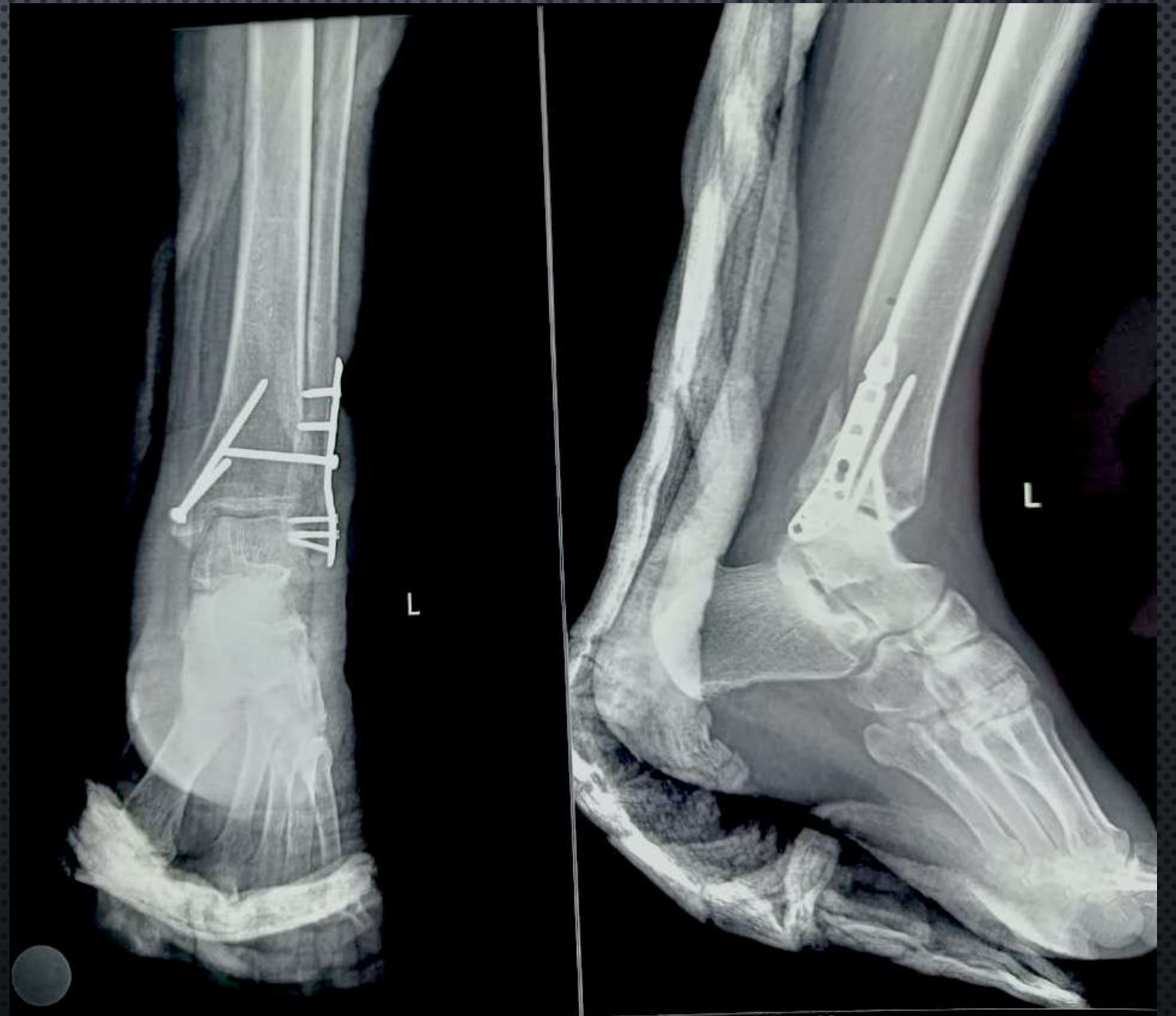# MEDIAL GUTTER CLEARING & MM FIXATION F/B

PUSH PULL **ALWAYS**



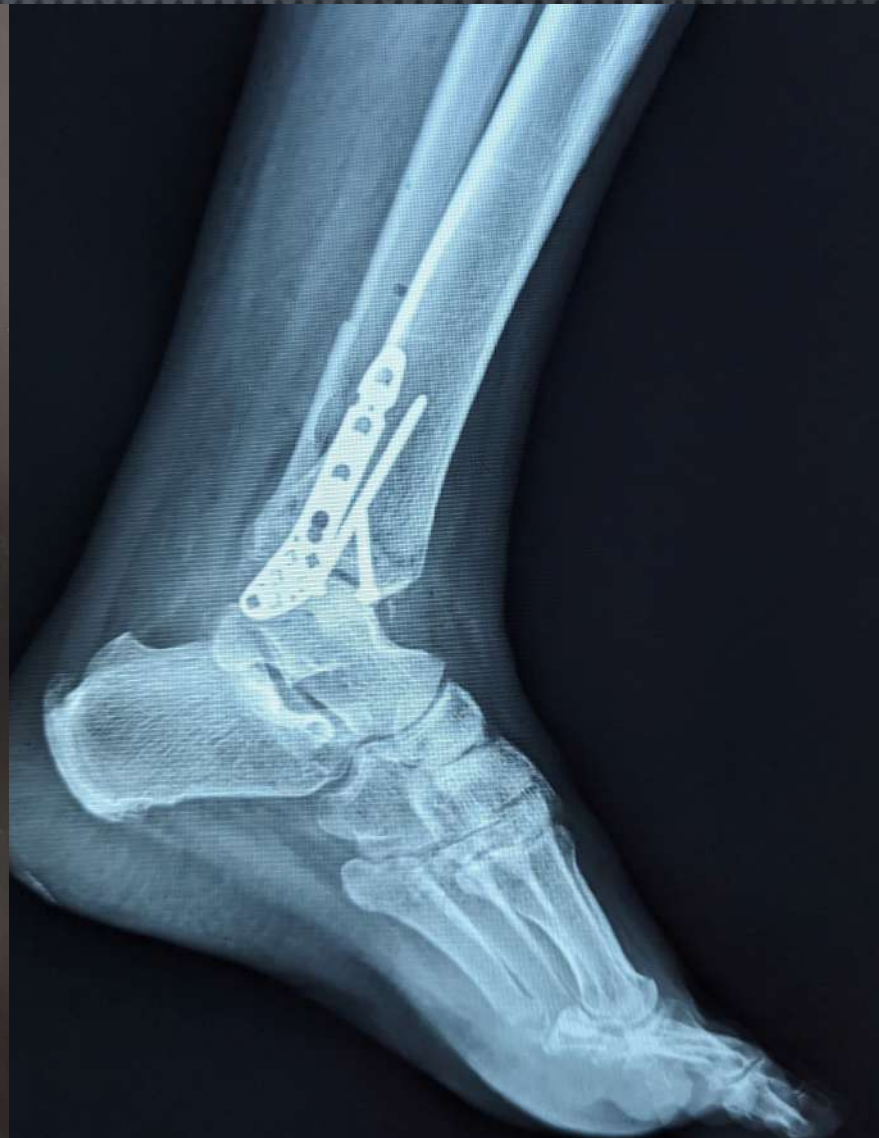
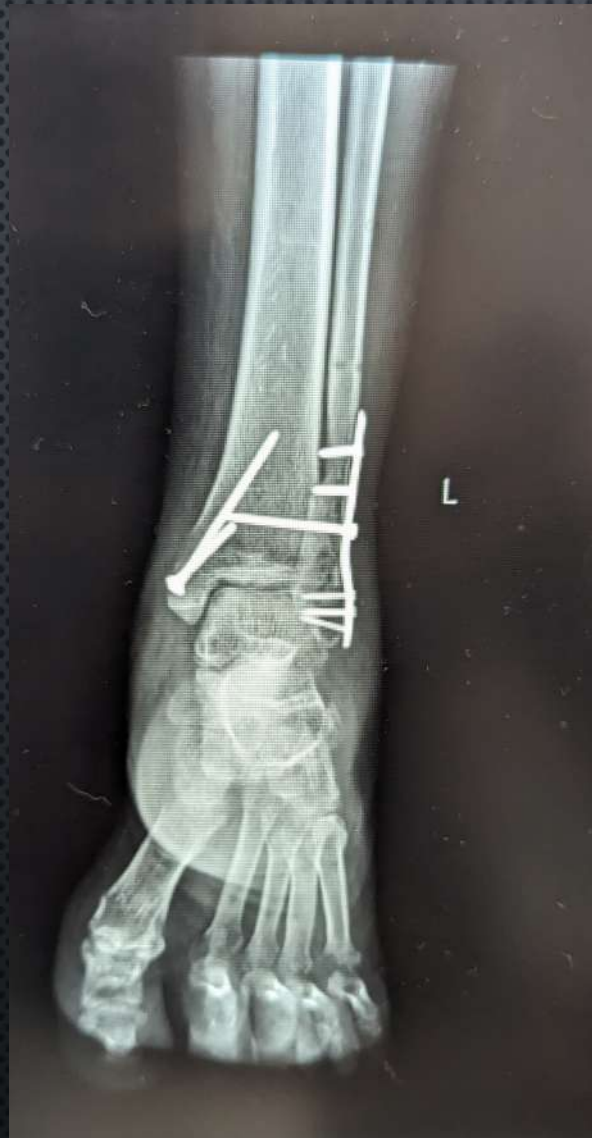
- IMMEDIATE POST OPERATIVE



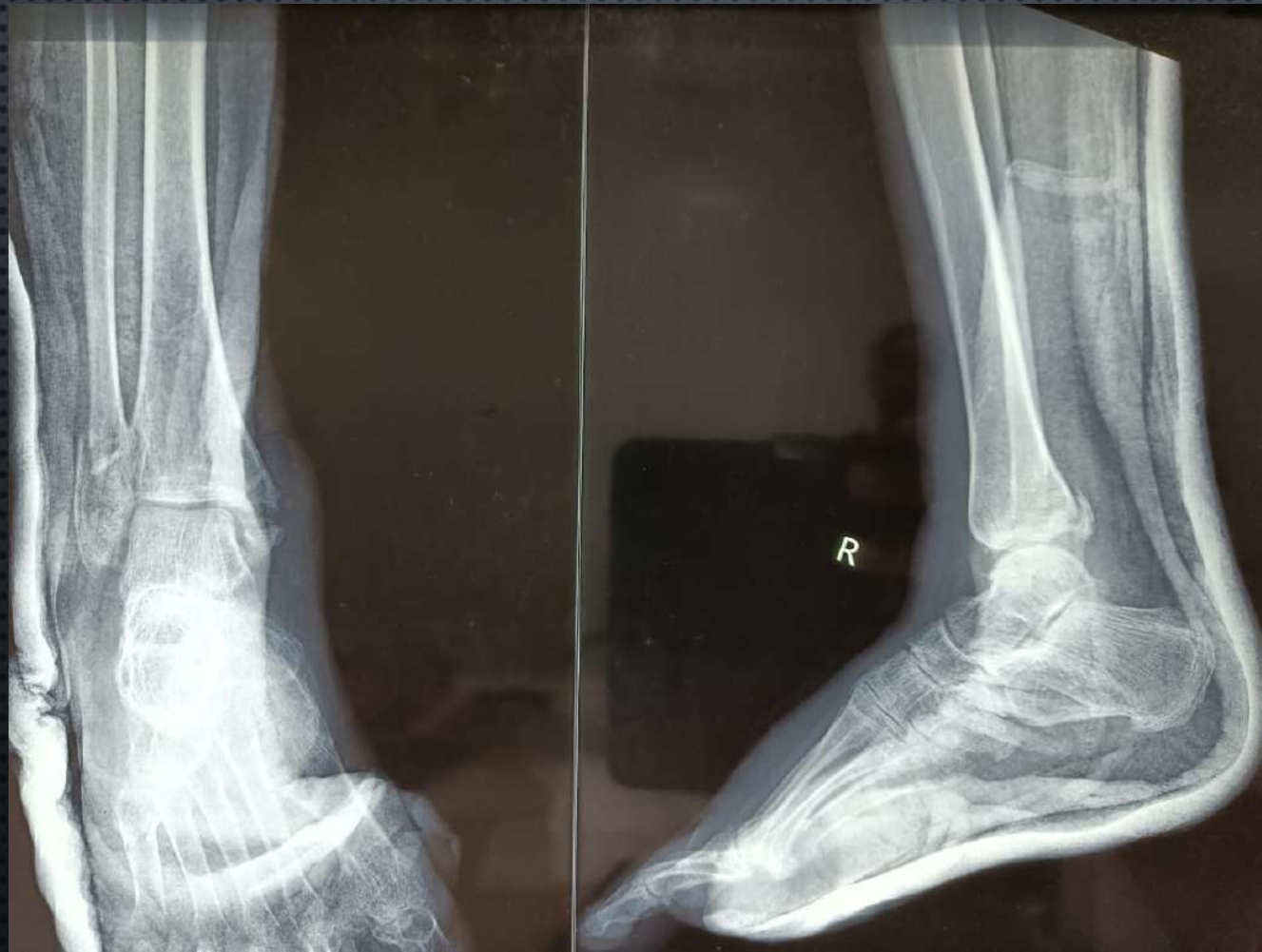

- FINAL FOLLOWUP



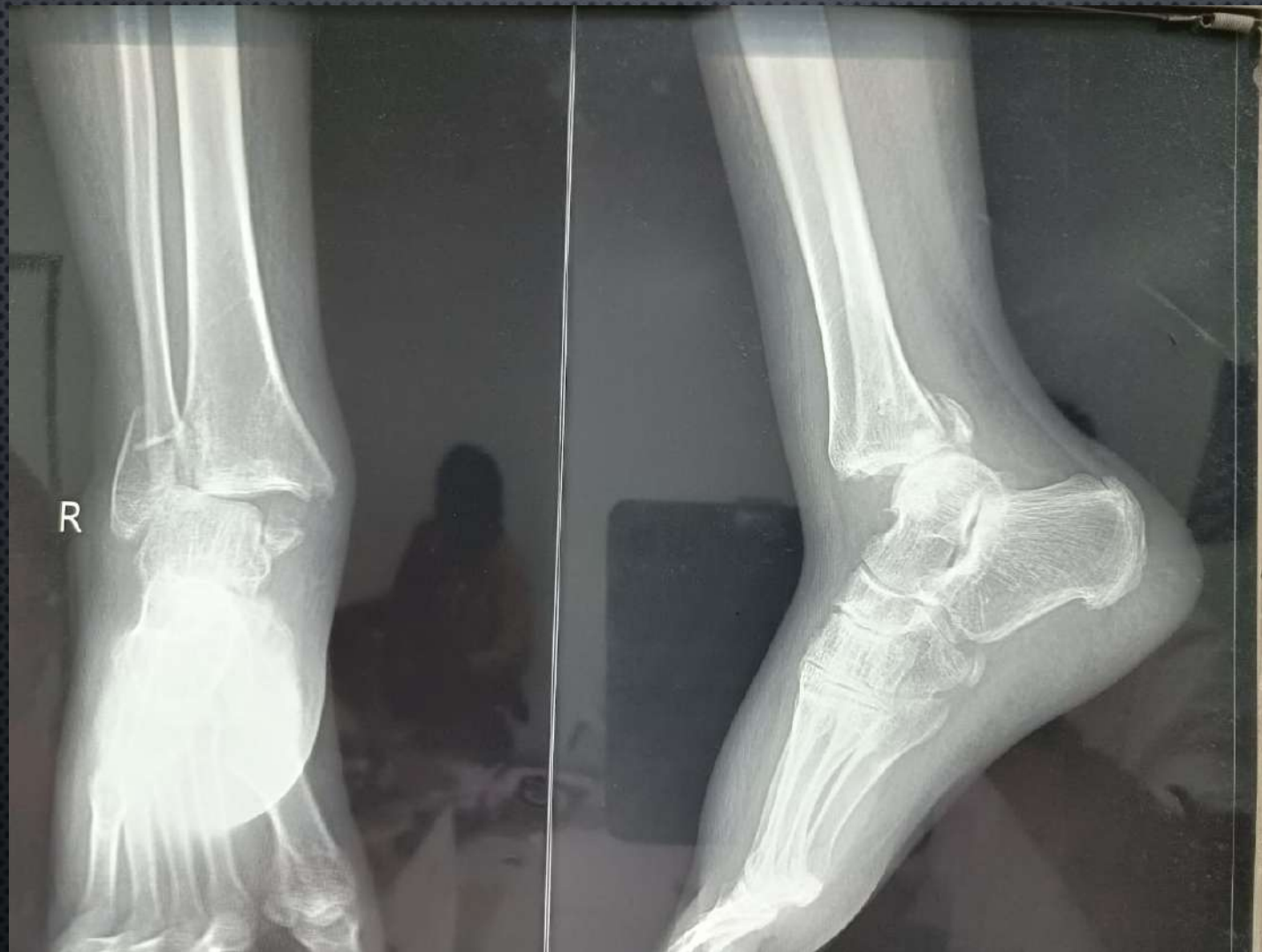

# TRI-MALLEOLAR NON UNION

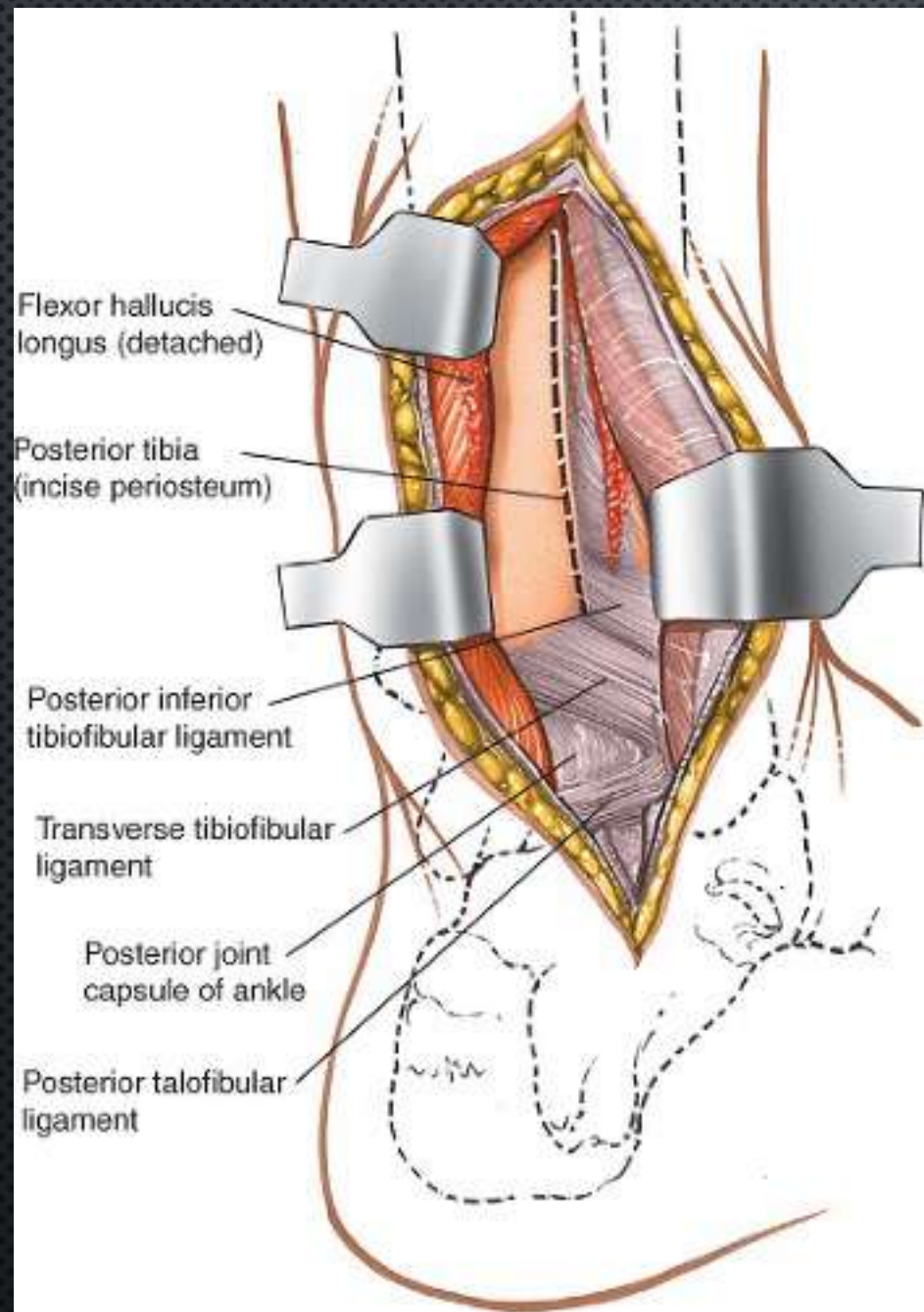




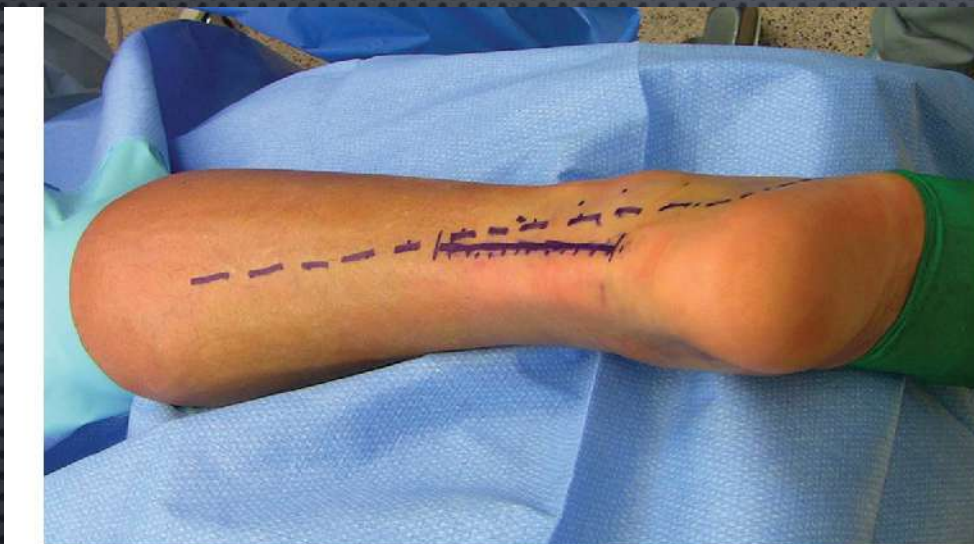# 7 MONTHS POST TRAUMA



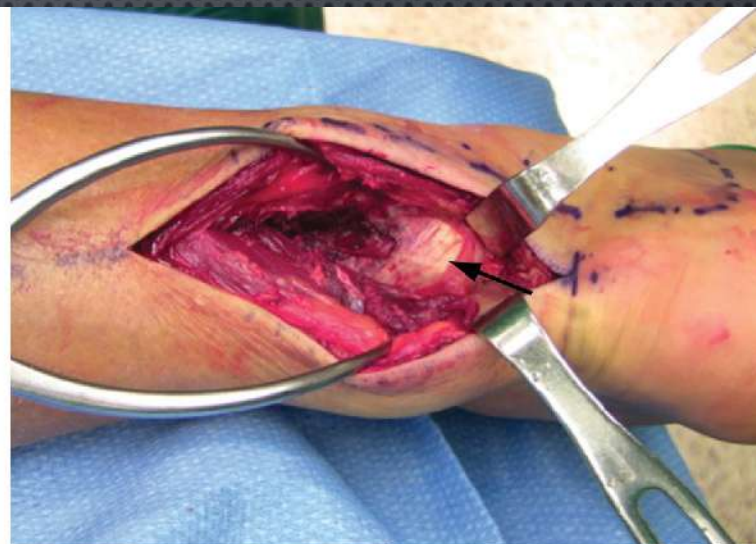




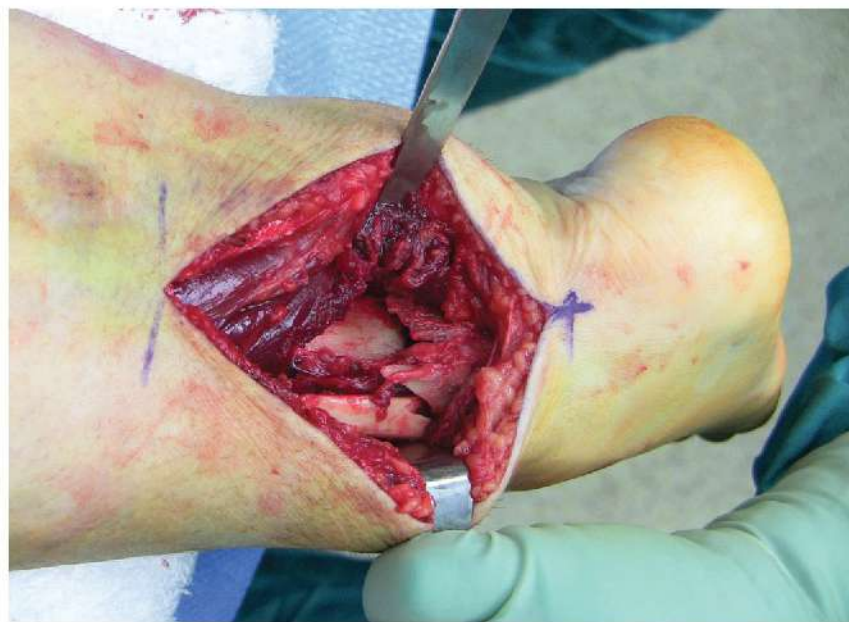


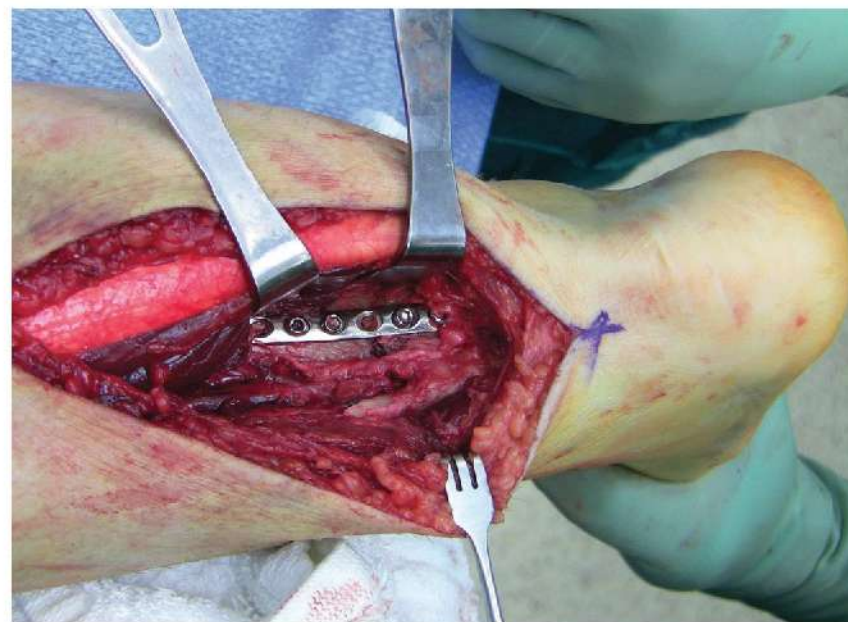
A



B

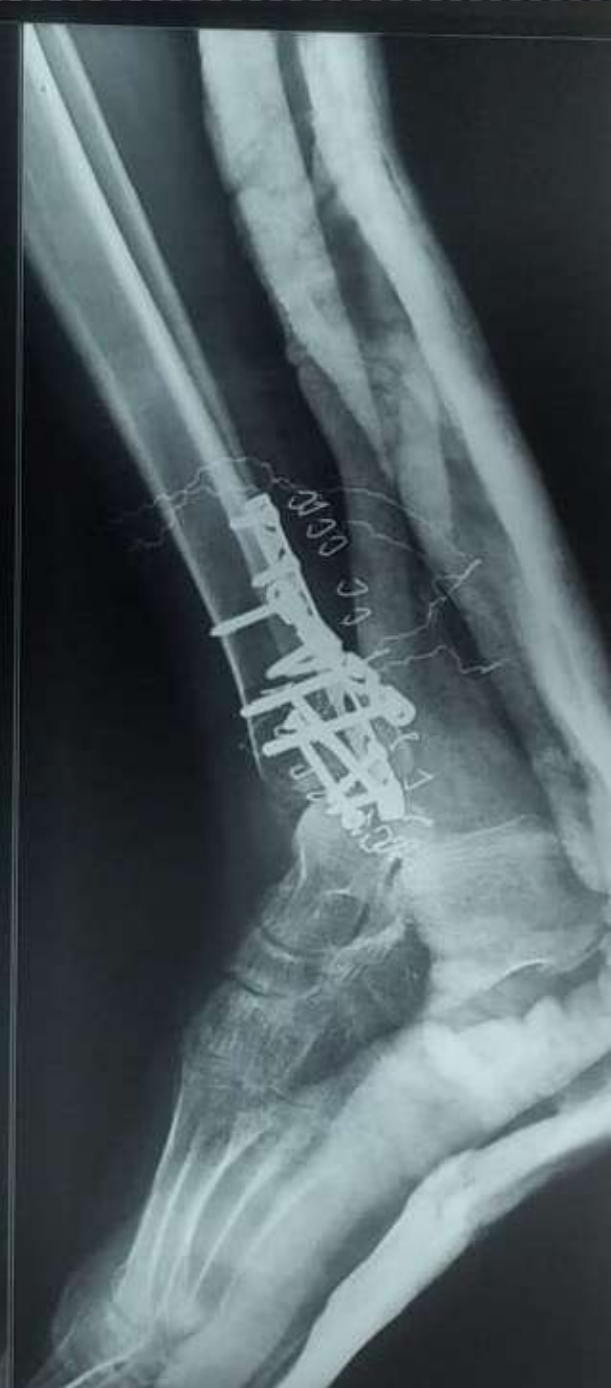
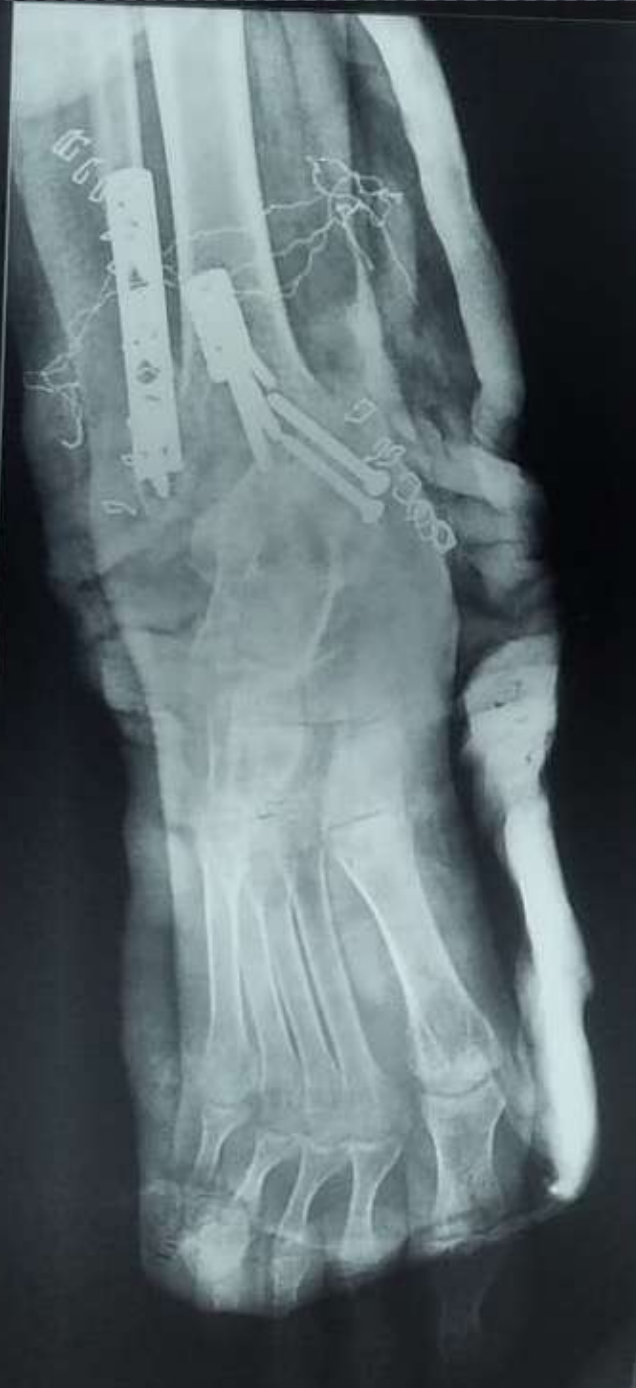
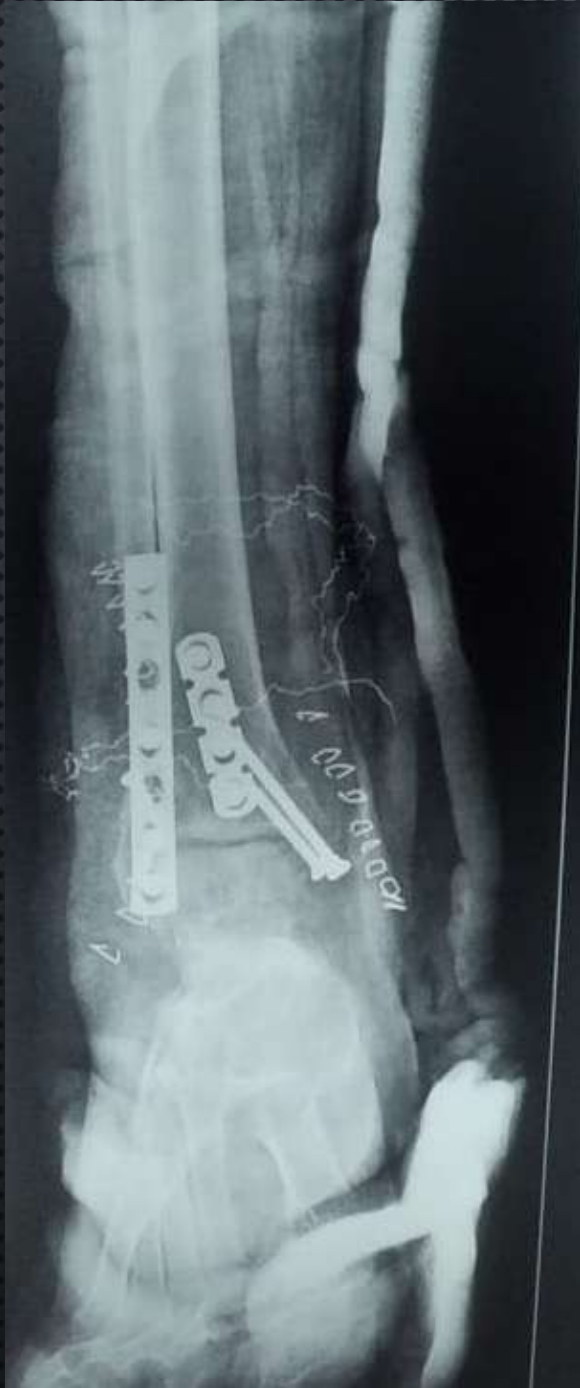C

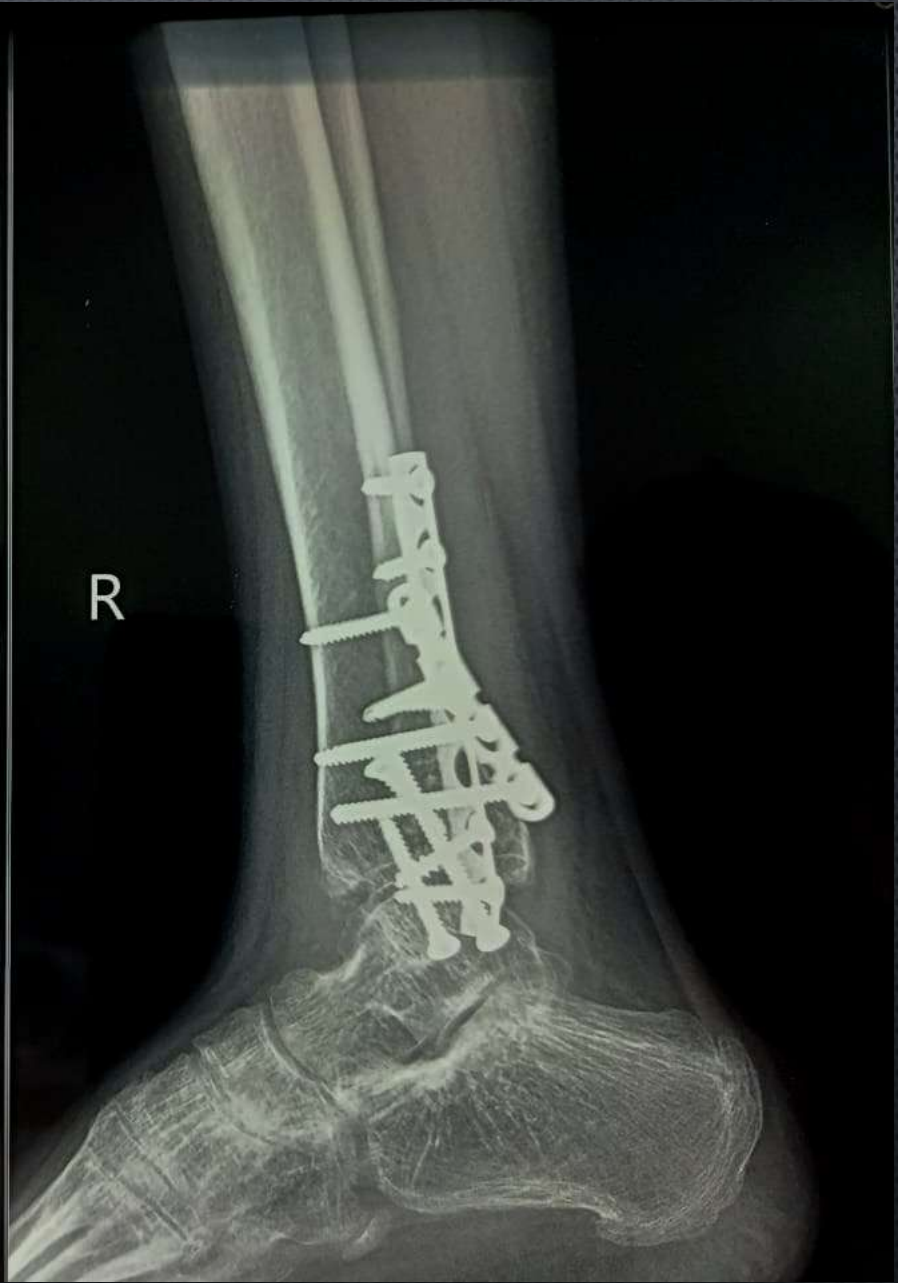
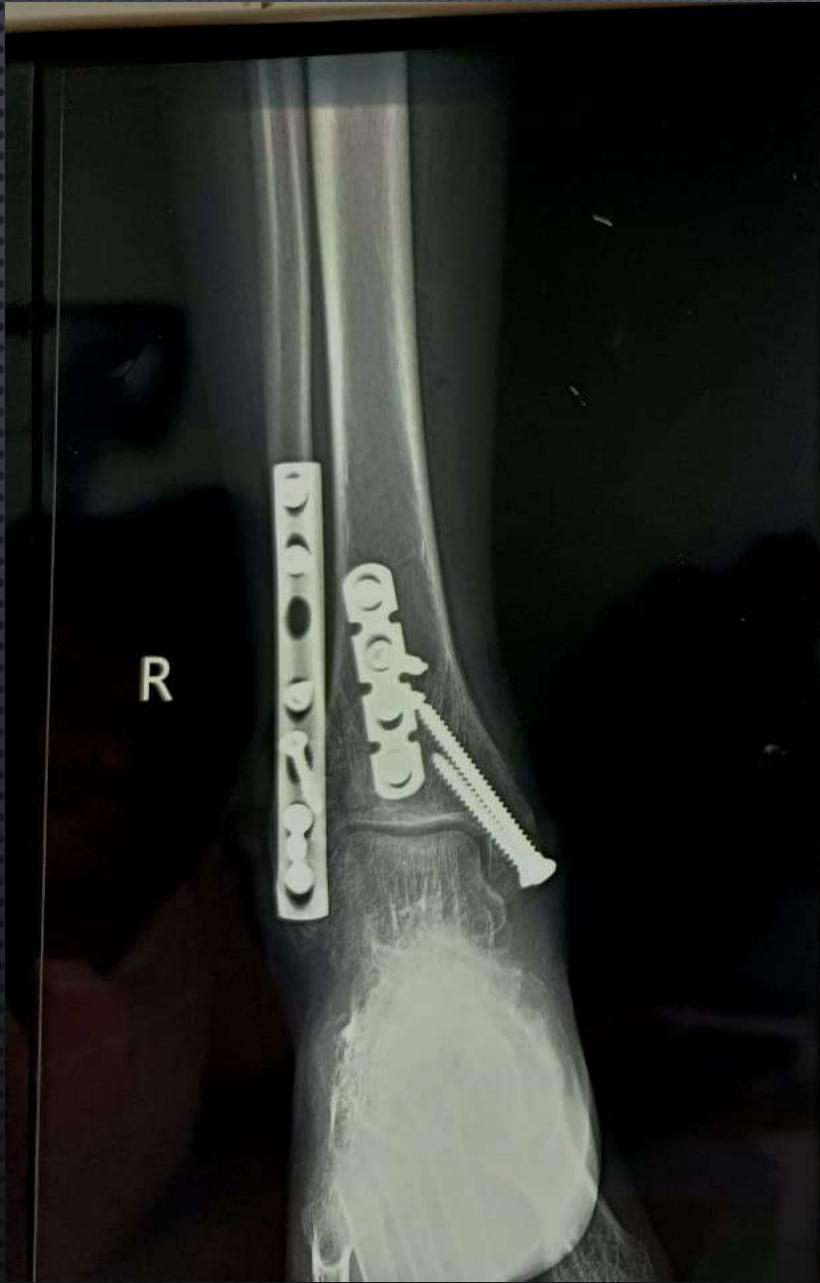
D

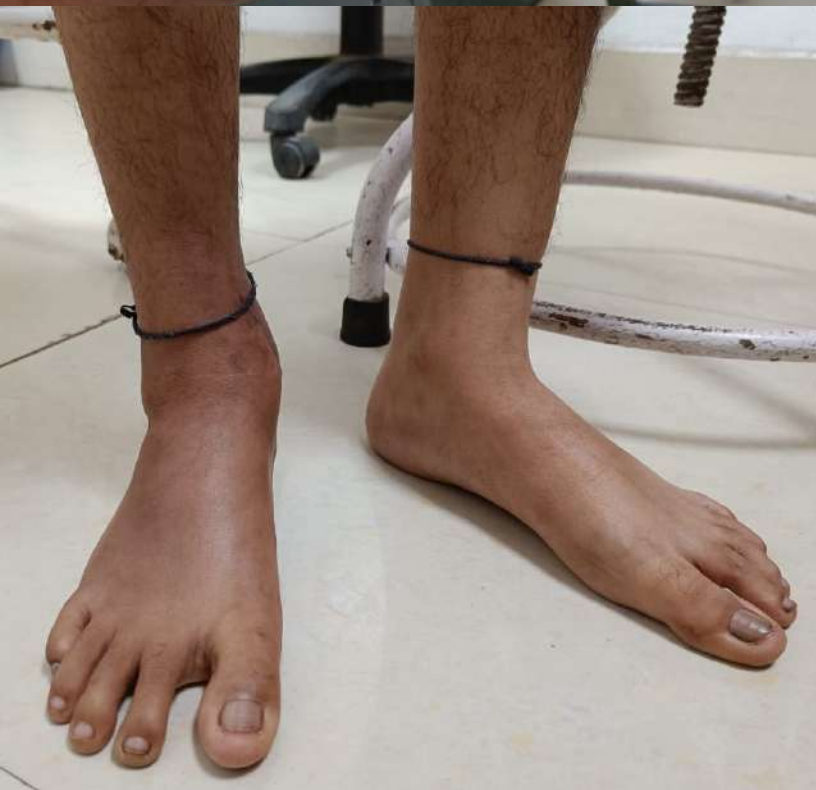
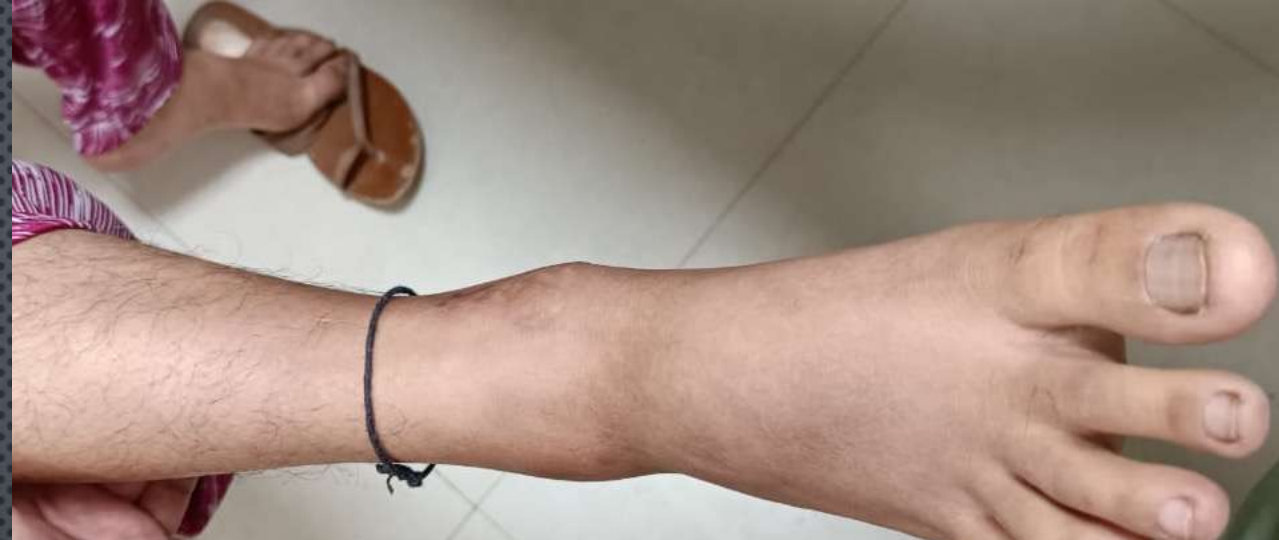
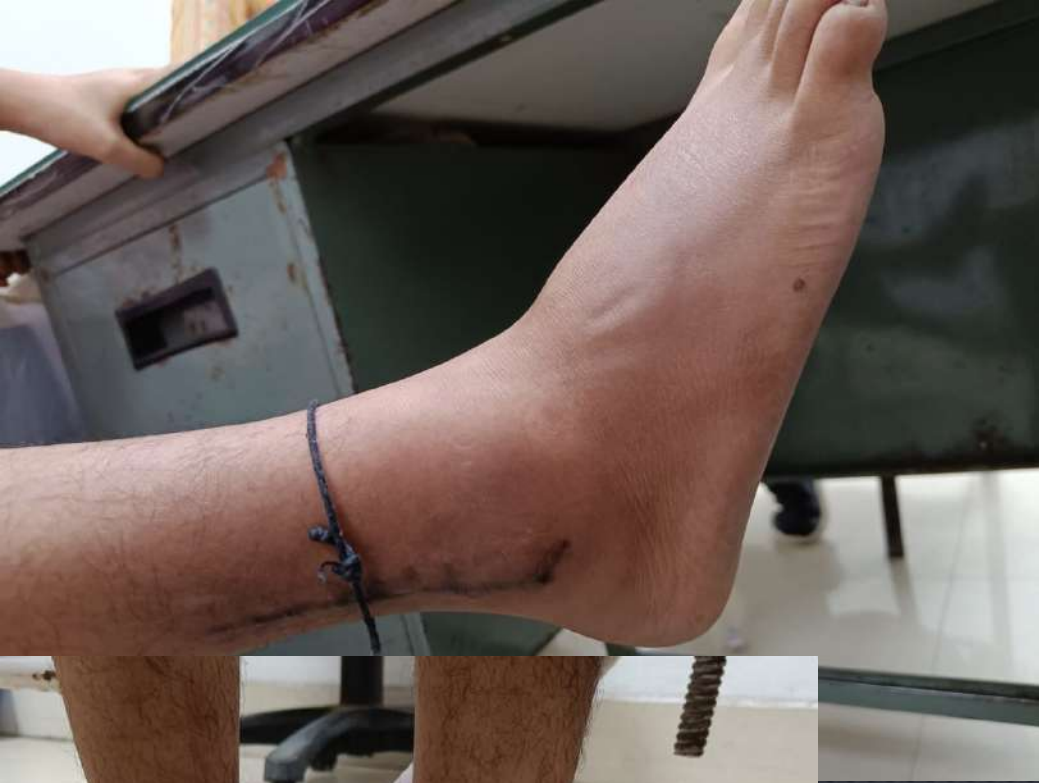




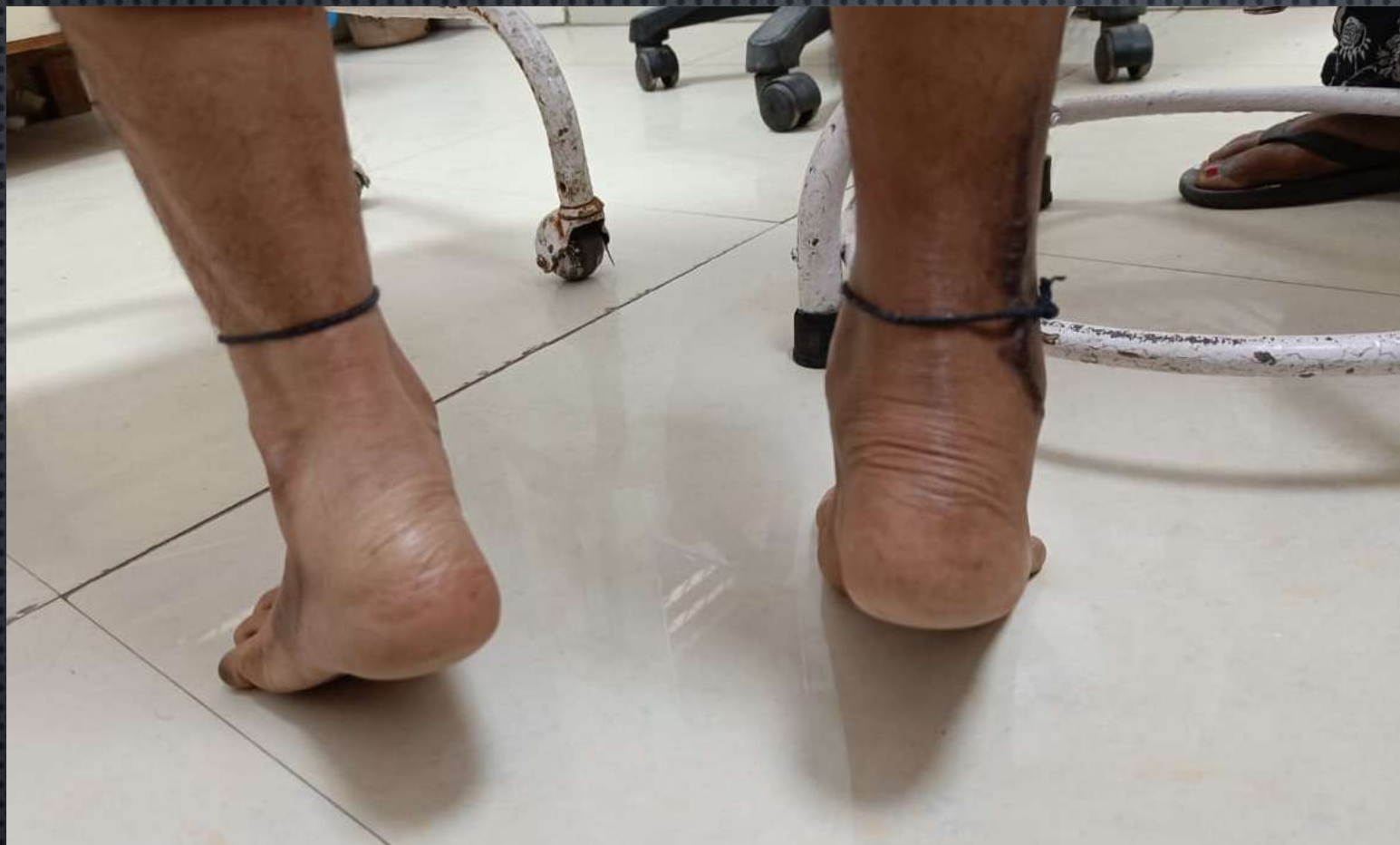










# SUMMARY

- *RARE ENTITY*
- *DEBILITATING PAIN AND LIMITED FUNCTION*
- *THOROUGH PREOPERATIVE EVALUATION*
- *OPTIMIZED WITH REGARD TO COMORBID MEDICAL CONDITIONS, SUCH AS DIABETES, VASCULAR DISEASE, AND MALNUTRITION, SMOKING CESSATION*
- *USE ADJUNCTS, SUCH AS BONE GRAFT, BMP, OR BONE STIMULATION*
- *MULTIMODAL APPROACH*
- *GOOD PATIENT OUTCOMES WITH MINIMAL COMPLICATIONS.*



THANK YOU